CLINICAL STUDIES ON DIAGNOSIS AND MANAGEMENT OF BENIGN PROSTATIC HYPERPLASIA IN DOGS

Kalyani Thakur[1], G.R. Bhojne[2], N.P. Dakshinkar[3], V.M. Dhoot[2], S.V. Upadhaye and A.S. Karamankar

[1]M.V.Sc. Student, [2]Assistant Professor, [3]Professor & Head, Department of Veterinary Clinical Medicine, Ethics & Jurisprudence, Nagpur Veterinary College, MAFSU, Nagpur – 440 006 (MHS.).

[Received: 28.3.2017; Accepted: 16.10.2017]

{DOI 10.29005/IJCP.2017.9.2.99-103}

The present study was done on 9 clinical cases of dogs suffering from benign prostatic hyperplasia. Objective and subjective assessments of the prostate gland were done using digital rectal palpation and ultrasonography. Fine needle aspiration using free hand technique was found simple, economical and efficient technique for obtaining good quality prostatic fluid sample for cytological diagnosis of benign prostatic hyperplasia in dogs. Treatment of benign prostatic hyperplasia with finasteride drug helped in resolving of the clinical signs, stabilization of the patient and reduction in the size of prostate volume in dogs.

Key words: Benign prostatic hyperplasia, Dogs, Finasteride, Prostate.

Benign prostatic hyperplasia (BPH) is the most common canine prostatic disorder present either grossly or microscopically in almost 100 per cent of sexually intact male dogs over the age of seven years, as well as in animals treated with androgenic hormones (Dhivya *et al.,* 2012). In a retrospective study of 140 cases of dogs with prostatic disorders diagnosed based on clinical signs, surgical examination or histopathology, more than 80% of intact male dogs over 5 years of age have either gross or microscopic evidence of benign prostatic hyperplasia (Hornbuckle *et al.,* 1978). Hyperplasia is probably due to an altered androgen: estrogen ratio, and requires the presence of the testes to start and continue to develop. Dihydrotestosterone (DHT) within the prostate gland probably serves as the main hormonal mediator for hyperplasia.

Materials and Methods

The study included nine cases diagnosed for benign prostatic hyperplasia at the Teaching Veterinary Clinical Complex, Nagpur Veterinary College, Nagpur during a period of 6 months (November 2015 – April 2016). The complete clinical examination of the male dogs was carried out proceeding with the owner's complaint, history of the patient, signalment of the patient and history of breeding records. Further, a thorough clinical examination was undertaken by considering the relevant points like sanguineous fluid dripping from tip of penis (Fig.1), colour of the discharge, presence of blood in urine or semen, constipation or ribbon-shaped defecation, difficult urination, stiffed legged gait appearance and occasional vomiting. Digital rectal examination (DRE) was carried out in standing position using gloved, lubricated index finger. One hand was used to palpate the caudo-ventral abdomen and the neck of the bladder and the prostate was pushed into the pelvic canal. Simultaneously the gloved, lubricated index finger of the other hand was used to perform digital examination of the caudal aspect of the prostate gland. The prostate gland was evaluated for the physical parameters like size, shape, symmetry, evidence of pain, surface contour and its position. Complete blood counts (CBC) were done using routine methods for determination of WBC count, RBC count, haemoglobin, haematocrit and platelet count. Urinalysis was performed using routine methods. Routine serum biochemical analysis was also performed.

The ultrasonographic examination of the prostate gland was undertaken in all nine cases suffering from benign prostatic hyperplasia for imaging the prostate parenchyma and to note the pathologies, if any. The prostate gland was imaged by ultrasonography to examine the echo texture of the prostatic parenchyma Fig.3. The prostate parenchyma was assessed for

Part of M.V.Sc. Thesis

homogenecity, cystic areas, echogenecity, vasculature and presence of calcification, if any. Prostatic fluid was collected from all dogs by transrectal fine needle aspiration method Fig.2. This aspirated prostatic fluid was expelled onto a clean, sterile glass slide. Smears were prepared and stained with Haematoxylin and Eosin and Papanicalau stain. The slides were observed for morphometric evaluation of prostatic cells cellularity, morphology and presence of inflammatory or abnormal cells Fig.4.

Fig. 1. Dripping of sanguineous fluid from the tip of urethera

Fig. 2. Transrectal fine needle aspiration of prostatic fluid

Fig.3. Sonogram of benign prostatic hyperplasia

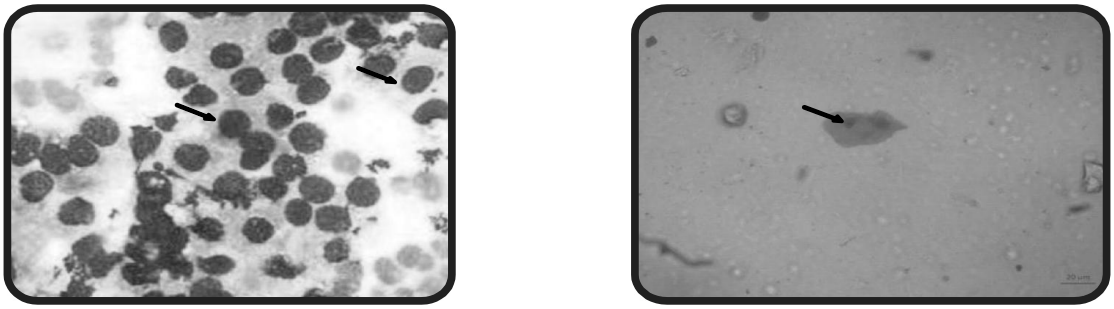

Fig. 4. Prostate gland showing polymorphic hyperplastic epithelial cells indicating benign prostatic hyperplasia and Clumps of epithelial cells

Dogs with benign prostatic hyperplasia (BHP) were treated with Finasteride @ 0.1 – 0.5 mg/kg, PO, every 24h with a maximum dose of 5mg per dog in dogs weighing 10-50 kg orally for a period of 30 days. Observations of various parameters recorded during the experiment period were tabulated and the data was statistically analyzed.

Results and Discussion

Based on history, symptoms, clinical investigation, blood haematology, serum biochemistry, urinalysis, digital rectal examination, ultrasonography and fine needle aspiration cytological findings, the dogs were diagnosed to be suffering from benign prostatic hyperplasia. All the dogs were sexually intact but were sexually inactive for

at least 3-5 years at the time presentation and were of 3-11 years old. Similar findings were reported by Dhivya *et al.* (2012) that the condition arises spontaneously in the gland as a consequence of ageing and endocrine influence and may begin as early as 2-3 years of age and may become cystic over 4 years of age. Limmanont *et al.* (2012) also reported that only dogs and humans develop this condition with high risk of BPH in old dogs, and it is usually found in at least 80% of the population of intact male dogs over 5 years of age. All nine dogs diagnosed with benign prostatic hyperplasia, showed sanguineous fluid dripping from the tip of the urethra. The next most common clinical sign observed was difficult urination in 66.66% cases, followed by hematuria in 55.55%, constipation and vomiting in 44.44% each and stiff legged gait in 11.11% of the cases. Similar observations were reported by Barsanti and Finco (1995) who documented constipation, intermittent haemorrhagic or clear light yellow urethral discharge or intermittent or persistent hematuria as the main clinical signs in dogs affected with BPH. Peter and Widmer (2003) also observed the clinical signs of sanguineous prostatic fluid, constipation and dysuria.

The mean rectal temperature and pulse rate were within normal range. Digital rectal examination revealed abnormal prostate gland, where 100% of cases showed mild to severe enlargement of the gland. The varieties of shape observed in the present study were walnut, irregular and ovoid where the irregular prostate gland was observed in the majority of cases. Seventy-seven per cent revealed asymmetrical prostate gland and 55% of dogs showed no evidence of pain during rectal palpation. The surface contour of prostate gland was smooth in 66% of dogs and rough in 33% of dogs. The positioning of prostate gland was observed fixed in 66% of dogs and movable in 33% cases. The observations of digital rectal examination are in compliance with Mukaratirwa and Chitura (2007) who also reported mild to moderate prostate enlargement of variable shape and asymmetry with no evidence of pain. However contrary to this, Romagnoli (2006) described abnormal prostate gland as a non-painful, symmetrically enlarged with variable consistency.

CBC analysis revealed WBC counts towards the higher side of the normal range (15743.65±1903.14 WBC/µL). The average haemoglobin concentration reported in dogs with BPH on the onset of study was observed as 12.51 ± 01.40 g/dl and the post treatment were 12.22 ± 01.44 g/dl and 12.55 ± 01.36 g/dl on 15th and 30th days respectively. Which were found non-significant (Table 1). The average percentage of neutrophil, lymphocyte, monocyte and eosinophil noted in dogs with BPH before the onset of study were observed as 76.88± 03.35, 17.77± 02.67, 04.22± 01.10 and 01.11± 00.30, respectively. The post treatment averages of the on 15th day were recorded as 84.55± 02.49, 11.55± 02.02, 04.44± 01.14 and 00.44± 00.24 per cent and on 30th day, the values were 76.66± 02.78, 14.44± 01.77, 07.33± 01.73 and 00.44± 00.24 per cent, respectively. All these values were found non-significant between 0, 15th and 30th day observations. These observations corroborate with the observations of Corrada *et al.,* (2004) and Romagnoli (2006) who also reported normal haemogram in dogs with BPH. The average serum total acid phosphates (TAP) on 0 day was observed as, 04.75± 00.61 U/L and the post treatment values were 03.62± 00.51 U/L on 15th day and 03.21± 00.51 U/L on 30th day. The average serum prostatic acid phosphates (PAP) was 03.3± 00.70 U/L on 0 day which changed to 01.95± 00.52 U/L on 15th day significantly ($P<0.05$) on 30th day (01.13± 00.35 U/L). Dakshinkar *et. al.* (2000) also observed significant increase in serum TAP and PAP activity in dogs with prostatic disease.

In dogs affected with BPH, the average urine specific gravity and urine pH reported on the onset of study were observed as, 01.02± 00.00 and 06.54± 00.25, respectively and nonsignificant post treatment averages on 15th day were 01.01± 00.00 and 06.61± 00.36 and on 30th day the values were 01.02± 00.00 and 06.84± 00.26 respectively.

Table 1 : Average ± S.E. of Hemato-biochemical and Urinary parameters in Benign prostatic hyperplasia

Sr. No.	Parameters	Day 0	Day 15	Day 30	Significance
	Haemato-biochemical				
1	Haemoglobin (g/dl)	12.51 ± 01.40	12.22 ± 01.44	12.55 ± 01.36	NS
2	Neutrophils (%)	76.88 ± 03.35	84.55 ± 02.49	76.66 ± 02.78	NS
3	Lymphocytes (%)	17.77 ± 02.67	11.55 ± 02.02	14.44 ± 01.77	NS
4	Eosinophils (%)	01.11 ± 00.30	00.44 ± 00.24	00.44 ± 00.24	NS
5	Monocytes (%)	04.22 ± 01.10	04.44 ± 01.14	07.33 ± 01.73	NS
6	TAP (U/L)	04.75 ± 00.61	03.62 ± 00.51	03.21 ± 00.51	NS
7	PAP (U/L)	03.3 [b] ± 00.70	01.95 ± 00.52	01.13 [a] ± 00.35	*
	Urine				
1	Specific gravity	01.02 ± 00.00	01.01 ± 00.00	01.02 ± 00.00	NS
2	pH	06.54 ± 00.25	06.61 ± 00.36	06.84 ± 00.26	NS

* = Significant at 5% level, NS – non significant
Different row-wise superscripts indicates significance

The cytological changes seen in benign prostatic hyperplasia were appearance of sheets of epithelial cells in monolayers with round to oval nuclei. The amount of cytoplasm was increased, giving the cells the polymorphic or polygonal appearance. However, in two cases, cell morphology was similar to normal prostatic epithelial cells, without change in shape. Cell borders were well defined and nuclear cytoplasmic ratio (N:C) was low. Clumps of cells were present in high numbers and were arranged in columns and large rafts. Kraft *et al.* (2008) recorded the similar findings in case of benign hyperplasia of prostate wherein, enlargement of cells with appearance in clumps was also observed with round to oval nuclei. Dakshinkar *et al.* (2008) noted well defined cell borders and low nuclear cytoplasmic ratio in benign prostatic hyperplasia. The ultrasound examination of benign prostatic hyperplasia revealed enlarged bilobed prostate with well defined, dense and diffusely hyperechoic parenchyma with homogenous echotexture at the neck of urinary bladder. These findings commensurate with Nyland and Matoon (2002) who described BPH as a subtle in homogeneity and echogenicity of the gland varying from diffusely homogenous and hypoechoic to hyperechoic. The cytological examinations confirmed the ultrasound findings in all cases of benign prostatic hyperplasia.

Efficacy of treatment was assessed based on the complete remission of clinical signs recorded on the initial day of presentation. At day 0, out of total nine dogs with BPH, fluid dripping was seen in 100% dogs, hematuria in 55.55%, constipation and vomiting in 44.44%, difficult urination in 66.66% and stiff legged gait in 11.11%. but after 15 days following treatment, it was seen that fluid dripping was seen in 55.55%, hematuria in 33.33% and constipation and difficult urination in 11.11% when stiff legged gait and vomiting was absent in all nine dogs. The signs gradually disappeared on 30th day of treatment when solitary case of fluid dripping and difficult urination was observed.

To conclude, fine needle aspiration using free hand technique was found simple, economical and efficient technique for

obtaining good quality prostatic fluid sample for cytological diagnosis of BPH. Digital rectal examination (DRE) as a screening test can be recognized as the least invasive and most convenient method for early detection of prostatic disease. Treatment with drug Finasteride was found effective in treating benign prostatic hyperplasia in dogs by mitigating the clinical signs and reducing size of prostate gland by ultrasound as well as on digital rectal examination.

References

Barsanti, J.A. and Finco, D.R. (1995). Medical management of canine prostatic hyperplasia. *In*: R. Kirk (Ed.), Current Veterinary Therapy XII, W. B. Saunders : Philadelphia, U.S.A. Pp.1033-1034.

Corrada, Y., Arias, D., Rodriguez, R., Spaini, E., Fava, F. and Gobello, C. (2004). Effect of tamoxifen citrate on reproductive parameters of male dogs. *Theriogenology*, **61**: 1327-1341.

Dakshinkar, N.P., Sarode, D.B. and Kothekar, M.D. (2000). Diagnosis of prostatic diseases in dogs. *Indian Vet. J.*, **77**: 948-950.

Dakshinkar, N.P., Dhoot, V.M. and Khan, W.A. (2008). Fine needle aspiration cytology of prostate in dogs. *Intas Polivet*, **9**(II): 191-194.

Dhivya, T.R., Sridevi, P., Kulasekar, K. and Kumrsamy, P. (2012). Incidence of benign prostatic hyperplasia in dogs. *Indian Vet. J.*, **33**(2): 54-55.

Hornbuckle, W.E., MacCoy, D.M., Allan, G.S. and Gunther, R. (1978). Prostatic disease in the dog. *Cornell Vet.*, **68**: 298-305.

Kraft, M., Brown, H.M. and LeRoy, B.L. (2008). Cytology of the canine prostate. *Irish Vet. J.*, **61**(5): 320-324.

Limmanont, C., Phavaphutanon, J. and Sirinarumitr, K. (2012). Effect of finasteride and deslorelin treatment on clinical signs, prostatic volume and semen quality in dogs with benign prostatic hypertrophy: A clinical trial. *Kasetsart J. (Nat. Sci.)*, **46**: 724-735.

Mukaratirwa, S. and Chitura, T. (2007). Canine subclinical prostatic disease: histological prevalence and validity of digital rectal examination as a screening test. *J. South African Vet. Assoc.*, **78**(2): 66-68.

Nyland, T.G. and Matoon, J.S. (2002). Prostate and Testes. *In:* Small Animal Diagnostic Ultrasound by T. G. Matoon and J. S. Nyland, 2nd edn., Saunders, Philadelphia, U.S.A. Pp. 250-266.

Peter, A.T. and Widmer, W.R. (2003). Prostatic Disorders. *In:* Small Animal Theriogenology, 1st edn., Elsevier Science, St. Louis, Missouri, U.S.A. Pp. 493-534.

Romagnoli, S. (2006) Two common causes of infertility in the male dog. 31st World Congress Proceeding, World Small Animal Veterinary Association, Prague, Czech Republic, Pp. 686-690.