CYSTIC ENDOMETRIAL HYPERPLASIA-PYOMETRA COMPLEX IN A NON-DESCRIPT CAT

B. Bibin Becha[1], Sunita Behera[1], G. Sudha[2] and A. Krishnaswamy[3]
[1]Ph.D. Scholar, [2]Associate Professor, [3]Professor and Head; Department of Veterinary Gynaecology & Obstetrics;
Veterinary College, KVAFSU, Hebb3al, Bengaluru – 560 024.
[Received: 23.3.2017; Accepted: 13.11.2017]

An eleven year old non-descript queen cat was presented with a history of foul smelling white pus discharge from the vagina for the past four days. The animal was anorectic, lethargic and anaemic with a highly distended, tensed abdomen and soiled perineal area. Vaginal smear revealed large numbers of degenerative neutrophils. Trans-abdominal ultrasonography revealed large anechoic pockets with thick walls anterior to the urinary bladder suggestive of endometrial hyperplasia with pyometra. Ovariohysterectomy was performed and the animal recovered uneventfully. The gross and microscopic appearance of the uterus with CEH-pyometra complex was described.
Key words: Cat, Cystic endometrial hyperplasia-pyometra, Ovariohysterectomy

Cystic endometrial hyperplasia-pyometra is a disease characterized by progesterone induced hyperplasia of the uterine endometrium with cystic dilatation of the endometrial glands and inflammation of the uterus with purulent content in the uterine lumen leading to several clinical signs (Agudelo, 2005). This disease is observed less commonly in cats compared to dogs. The low occurrence in cats is attributed to less exposure to progesterone as they are induced ovulators and therefore lower risk of development of disease (Lawler *et al.*, 1993). The clinical presentation, diagnosis and treatment of open pyometra (Hayati *et al.*, 2016) and surgical management of closed pyometra (Kalita *et al.*, 2013) in queen cats have been reported.

CEH is commonly found in nulliparous queens aged more than 5 years whereas pyometra is more common in queens older than 8 years (Lucas *et al.*, 2000). There is no correlation between the development of pyometra with the age at first mating or parturition. Presence of corpora lutea was reported in 40–70 per cent of pyometra cases (Johnson, 1994). In queens, pyometra has also found in follicular phase (15–23 %) due to cystic ovary which is influenced by oestrogen along with progesterone (Von-Reitzeinstein *et al.*, 2000).

Case History and Observations

An 11 – year old non-descript queen cat was presented to the clinics with a history of foul smelling white pus discharge from the vagina for the past four days. The animal was anorectic and lethargic with a highly distended abdomen and soiled perineal area. As narrated by the owner, the animal had recovered from pyometra after medical management a year ago. Animal had exhibited signs of oestrus approximately 30 days back and was kept indoors to prevent breeding.

On clinical examination, queen cat was found to be anaemic and had tensed abdomen. Vaginal smear revealed large numbers of degenerative neutrophils. Trans-abdominal ultrasonography revealed large anechoic pockets with thick walls anterior to the urinary bladder suggestive of endometrial hyperplasia with pyometra (Fig. 1).

Haematology revealed a total RBC count of 6.92 millions/µl (Ref. range: 7.5–10.5 millions/µl), WBC count of 2900/µl (Ref. range: 5500–19,500/µl), PCV 27 % (Ref. range: 30–45 %), Haemoglobin 8.9 g/dl (Ref. range: 10–15 g/dl), platelet count of 60,000/µl (Ref. range: 2,00,000–5,00,000/µl) and serum creatinine, ALT, total protein and glucose levels of 1.2 mg/dl (Ref. range: 0.8–2.0 mg/dl), 312 U/L (Ref. range: 10–80 U/L), 7.7 g/dl (Ref. range: 5.4–7.8 g/dl) and 127 mg/dl (Ref. range: 75–160 mg/dl), respectively. Haematology indicated anaemia, leukopenia, thrombocytopenia with elevated ALT levels in the animal. Based on history, clinical findings, ultrasonography and haematology, the condition was diagnosed as endometrial hyperplasia-pyometra complex

and with the consent of the owner, it was decided to perform ovariohysterectomy.

Fig. 1. Abdominal ultrasonography showing large anechoic pockets with thick wall

Fig. 2. Enlarged uterine horns containing pus, thickened wall and multiple CLs in ovaries

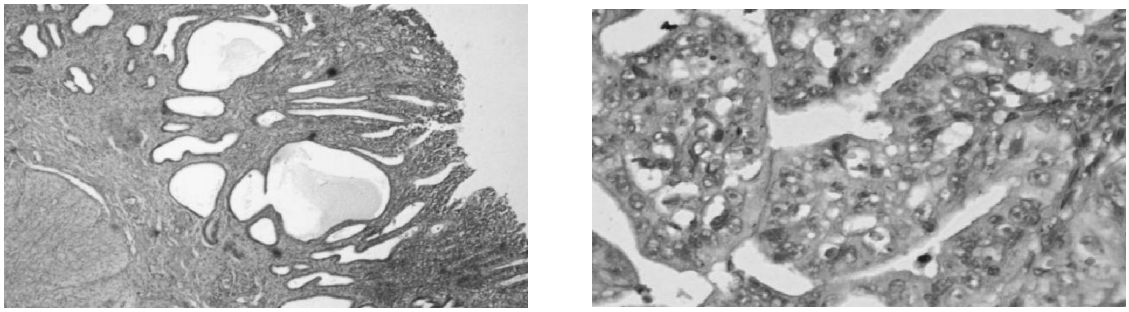

Fig. 3. Histopathology of uterus showing highly proliferated endometrium with dilated endometrial glands (100× and 400×)

Treatment and Discussion

Ovariohysterectomy was performed through the midventral abdominal approach under general anaesthesia by parenteral administration of a combination of xylazine and ketamine (Xylazine @ 1 mg/Kg body wt. and ketamine @ 20 mg/Kg body wt.). The abdominal incision was closed by standard surgical procedure. The animal was treated orally with Cephalexin @ 25 mg/Kg body weight thrice daily and alternate day wound dressing was followed. Animal had an uneventful recovery by 12 days of surgery.

On gross examination, the uterine horns were enlarged, round and turgid, measuring 10 cms each in length and 2.5 cm in diameter. Both ovaries had several corpora lutea. Uterine wall was thick and the lumen contained serosanguinous material (Fig. 2). Representative tissue samples of uterine horns were collected, preserved in 10 per cent buffered formalin solution and processed for histopathologyical studies. Histopathology revealed cystic dilatation of endometrial glands and proliferation of endometrial glandular epithelium and fibrous tissue. Cytoplasmic vacuolations of glandular

epithelial cells and polymorphonuclear infiltrations were also observed (Fig 3).

Vaginal mucopurulent discharge or haemorrhagic discharge in patients with pyometra was obseved but sometimes the discharge was not noticed due to cleaning habit of the queens as also reported by Barsanti (1998). Abdominal distension and enlarged uterus was there during abdominal palpation of the queen with pyometra as also recorded by Johnson (1994). Other clinical signs detected during pyometra were anorexia, vomiting, lethargy, loss of weight and in severe cases dehydration and hypothermia.

Haematology revealed anaemia due to chronic inflammation and toxic effect that suppress erythropoesis as also reported by Johnson (1994). Leukopenia can be observed in five per cent of pyometra cases which is seen in this case alo. Hyperproteinaemia was due to dehydration or sinflammatory process. Ultrasound used as a confirmatory diagnostic tool for differential diagnosis of pyometra with pregnancy and ascites. The ultrasonographic observations have been made as thickened endometrium and small anechoic or hypoechoic pockets in uterus due to presence of mucus, haemorrhagic or necrotic accumulations as also mentioned by Davidson (1995).

Gross observations of uterus in CEH-pyometra include thickness of endometrium due to hyperplasia and expansion of endometrial glands. There was shedding of superficial epithelium, presence of haemorrhagic areas and pus accumulation in the uterus. Histopathology findings were atrophy of endometrium and endometrial glands and also infiltration of endometrium by lymphocyte and neutrophils indicating inflammation as also reported by Dong *et al.* (2013).

It was concluded that CEH–pyometra complex in female cats can be diagnosed by clinical signs, abdominal palpation, ultrasonography and can be confirmed by histopathology. Treatment options include surgical/medical management along with supportivetherapy.

References

Agudelo, C.F. (2005). Cystic endometrial hyperplasia-pyometra complex in cats – A review. *Vet. Q.*, **27**(4): 173-182.

Barsanti, J.A. (1998). Genitourinary Infections. *In:* Infectious diseases of the Dog and Cat. Green, C.E. (Eds.). 2nd edn., W.B. Saunders Co., Philadelphia, U.S.A. Pp. 643-644.

Dong, W.Y., Jiang, C.Y. and Qian, C.Z. (2013). Histopathological observations on the uterus and ovary of a cat with pyometra. *Pak. Vet. J.,* **33**(3): 395-397.

Davidson, A.P. (1995). Medical treatment of pyometra with prostaglandin $F_{2\alpha}$ in the bitch and queen. *In:* Current Veterinary Therapy XII. Bonagura, J.D. and Kirk, R.W. (Eds.), 1st edn., W.B. Saunders Co., Philadelphia, U.S.A. Pp. 1163-1165.

Hayati, F., Ahrari-Khafi, M.S., Hassankhani, M., Mansourian, M. and Asghari, S. (2016). A rare radiographic appearance of a calcified uterus in a queen with pyometra: a case report. *Vet. Med.*, **61**(6): 357-306.

Johnson, C.A. (1994). Female reproduction and disorders of the female reproductive tract. *In:* The Cat. Diseases and Clinical Management, Vol. 2, Sherding, R. (Eds.). 2nd edn., Churchill Livingstone, New York, U.S.A. Pp. 1855-1876.

Kalita, D., Sajesh, M.G. and Bhuyan, D. (2013). Surgical management of pyometra in a cat. *Indian J. Vet. Surg.*, **34**(1): 76.

Lawler, D.F., Johnston, S.D., Hegstad, R.L., Keltner, D.G. and Owens, S.F. (1993). Ovulation without cervical stimulation in domestic cats. *J. Reprod. Fertil. Suppl.*, **47**: 57-61.

Lucas, S.S., Oliveira, A.L. and Wallau, J.E. (2000). Pyometra in Dogs and Cats: Review of 103 cases. Revista da Faculdade de Zootecnia, *Veterinariae Agronomia Uruguaiana*, **7**: 99-103.

Von-Reitzeinstein, M., Archbald, L.F. and Newell, S.M. (2000). Theriogenology question of the month. Pyometra, hydrometra or mucometra. *J. Am. Vet. Med. Assoc.*, **216**: 1221-1223.