PERINEAL HERNIOPLASTY USING MURINE ACELLULAR DERMAL MATRIX AS A BIOLOGICAL MESH IN A DOG

Dayamon D. Mathew[1], V. Remya, S.K. Maiti[2], A.K. Sharma[2] and Naveen Kumar[2]
[1]Ph.D..Scholar, [2]Principal Scientist, Division of Surgery, ICAR-Indian Veterinary Research Institute, Izatnagar-243122, Bareilly, Uttar Pradesh.
[Received: 13.1.2017; Accepted: 04.9.2017]

Perineal hernia results from failure of the muscular pelvic diaphragm to support the rectal wall, which stretches and deviates. Pelvic and abdominal contents may protrude between pelvic diaphragm and the rectum. The cause of the muscular deterioration could be one or combination of the following pathological processes: muscular atrophy, myopathies, hormonal influence and prostatic hypertrophy. The disease occurs commonly in males and is associated with constipation, obstipation, dyschesia, a soft perineal swelling and occasionally urinary problems (Bellenger and Canfield, 2002).

Perineal hernia may be associated with sacculation, dilatation, deviation and diverticulation of rectum, retroflexion of urinary bladder or uretral obstruction (Vnuck *et al.,* 2006). The recurrence of the hernia, tenesmus and rectal prolapsed are not rare with standard herniorraphy (Brissot *et al.* 2004). Internal obturator flap technique has been used frequently and the recurrence rate declined to 2-10% (Vnuck *et al.,* 2006). Castration is recommended due to the effects of testosterone (Head and Francis, 2002) or relaxin on the prostate gland and perianal musculature. Large rectal sacculation and rectal diverticulum may cause straining to expel faeces and may lead to disruption of the perineal hernia repair. Therefore, surgical correction of rectal diverticulum or large sacculation should be carried out to prevent recurrence of perineal hernia (Vnuck *et al.,* 2006). Colopexy, cystopexy or vas deferens pexy are also suggested for prevention of recurrence of rectal herniation (Brissot *et al.* 2004). Adequate analgesia protocol is also needed for prevention of straining and concomitant recurrence. For the repair of perineal hernia in dogs synthetic materials were used.

Part of Ph.D. Thesis

Case History and Observations

An eight years old non-descript intact male dog was presented to the Veterinary Polyclinic with a history of swelling on the right peri-anal region since 3 weeks. The dog was having difficulty in passing faeces. The animal had normal urination. On clinical examination, the animal was bright, alert and active with a good physical condition (body condition score of 5/9). Rectal temperature, heart and respiratory rates were within normal limits. Oral as well as conjuctival mucous membranes were pale pink and capillary refill time was less than 2 sec. On per-rectal examination, a faeces filled laterally deviated sacculation was observed which was seen as a bulging on the peri-anal region. The case was diagnosed as perineal hernia and it was decided to repair the defect with murine acellular dermal matrix.

Treatment

Preparation of Murine Acellular Dermal Matrix

Fresh skin was obtained from Sprague–Dawley rat of approximately 300 gm body weight immediately following sacrifice for other research work and then stored at 4 ^{0}C in phosphate buffered saline (PBS, pH 7.4) containing 0.1 % amikacin and 0.2025 ethylenediaminetetraacetic acid (EDTA). The skin consisted of epidermis and dermis, without the overlying hair, was washed with PBS before being placed in hypertonic solution (605 mg tris base, 4 g sodium chloride, 202.5 mg EDTA in 100 ml PBS) at room temperature for 8 h on a shaker. Following soaking in hypertonic solution, epidermal layer of skin was removed and then washed in PBS on a shaker for 1 h. The

cellular dermis was then placed in 0.5% sodium dodecyl sulphate (SDS) on an orbital shaker. After 48 h of detergent treatment was qualitatively analyzed histologically with hematoxylin and eosin staining for cell nuclei and extra cellular matrix morphology. The result shows that matrix was completely acellular. The resulting matrix was six times rinsed (2 h each) with PBS under constant agitation (180 rotation per minute) on an orbital shaker to remove the residual chemicals. Prepared decellularized matric was stored in sterile PBS solution containing 0.1 % amikacin and 0.1 % sodium azide at -20 ^{0}C .

Surgical Procedure

The animal was kept off-feed and water was also with-held for 12 hours prior to surgery. Just before surgery the animal was given enema to clear the faeces from the rectum. The animal was premedicated with atropine sulphate (0.045 mg/kg body weight intramuscularly) following this pentazocine was administered (1 mg/kg body weight intra-muscularly). Later the animal was pre-anaesthetised with diazepam (0.5 mg/kg body weight intra venously) and the anaesthesia was induced with ketamine (5 mg/kg body weight intravenously) and maintained using a combination of ketamine and diazepam. The antibiotic prophylaxis was provided with ceftriaxone (20 mg/kg body weight intra-venously) and preemptive analgesia was provided with meloxicam (0.2 mg/kg body weight intravenously).

The animal was prepared aseptically for surgery by clipping and shaving the hair over the bulged perianal region. The animal was positioned on sternal recumbency. A purse string suture was applied prior to start of surgery to prevent intra-operative contamination of the surgical area. A curvilinear skin incision was made on the right perianal region starting from the base of the tail till the ventro-lateral aspect of the anus. Carefully the skin was separated and the muscles were also separated. A bulged part of the rectum was found and was diagnosed as rectal diverticulum (Fig. 1). The diverticulum was corrected and the intestine was reduced. The muscles of the pelvic diaphragm were very weak making the closure of the ring difficult so it was decided to go for hernioplasty with acellular dermal matrix of rat origin. According to the shape of the ring, murine acellular dermal matrix was cut and was sutured to close the hernial ring using silk no. 1 in an interrupted fashion (Fig. 2). The subcutis was sutured routinely using no. 2/0 chromic catgut. The skin was closed using silk no. 1 in horizontal mattress pattern. The wound was cleaned and dressed with povidone iodine solution.

Fig. 1: Showing bulge part of the rectum and was diagnosed as rectal diverticulum

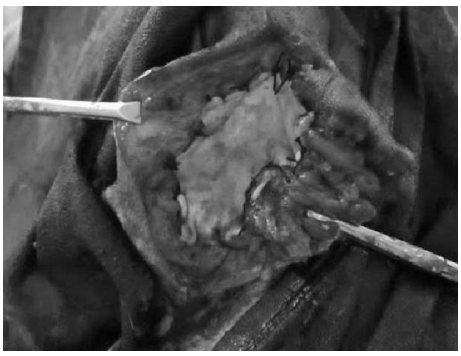

Fig. 2: Murine acellular dermal matrix was cut and was sutured as per the shape of the ring to close the hernial ring using silk no. 1 in interrupted fashion

The animal was adviced for ceftriaxone twice daily for 5 days, metronidazole once daily for 5 days and melaxicam for 3 days post-operatively along with B-complex vitamin injection. The animal was kept completely on fluids (inj.

Normal saline and Ringers Lactate) for 7 days post-operatively and then advised to slowly introduce the liquid diet for next 5 days. The skin sutures were removed on 8th post-operative day.

Results and Discussion

Hernioplasty is usually done if the hernial ring is large or if the strength of the muscles around the ring is less to hold the sutures. In the present report we use murine acellular dermal matrix for the repair of large perineal hernia in a dog. In the present report we use murine acellular dermal matrix for the repair of large perineal hernia in a dog. Though other reporters have reported the use of indifferent materials like Vnuck *et al.* (2006) reported that perineal hernioplasty can be done using synthetic materials like polypropylene mesh; Lee *et al.* (2012) reported by natural scaffolds like canine small intestine submucosa allograft and Frankland (1986) porcine dermal collagen sheet as biomaterial. The antibiotic coverage provided was found to be satisfactory and there was no infection till the removal of the sutures. The animal had an uneventful recovery.

Conclusions

A successful case of perineal hernioplasty using murine acellular dermal matrix as a biological mesh in a dog is described.

References

Bellenger, C.R. and Canfield, R.B. (2002). Perineal Hernia. *In:* Slatter D. (Eds): Textbook of Small Animal Surgery. 3rd edn. Saunders, Philadelphia, U.S.A. Pp.487–498.

Brissot, H.N., Dupre, G.P. and Bouvy, B.M. (2004). Use of laparotomy in a staged approach for resolution of bilateral or complicated perineal hernia in 41 dogs. *Vet. Surg.,* **33**: 412-421.

Frankland A.L. (1986). Use of porcine dermal collagen in the repair of perineal hernia in dogs- a preliminary report. *Vet. Rec.,* **119**: 13–14.

Head, L.L. and Francis, D.A. (2002). Mineralized paraprostatic cyst as a potential contributing factor in the development of perineal hernias in a dog. *J. Am. Vet. Med. Assoc.,* **221**: 533-535.

Lee, A.J., Chung, W.H., Kim, D.H., Lee, K.P., Suh, H.J., Do, S.H., Eom, K. and Kim, H.Y. (2012). Use of canine small intestinal submucosa allograft for treating perineal hernias in two dogs. *J. Vet. Sci.,* **13**: 327-330.

Vnuck, D., Maticic, D., Kreszinger, M., Radisic, B., Kos, J., Lipar, M. and Babic, T. (2006). A modified salvage technique in surgical repair of perineal hernia in dogs using polypropylene mesh. *Vet. Med-Czech.,* **51**: 111-117.