VULVO-VAGINAL LEIOMYOMA AND ITS SURGICAL MANAGEMENT IN TWO DOGS

Jayakrushna Das[1], Snehasis Pradhan[2], Rudrashis Sethi[2] and Jasobanta Pradhan[2]
[1]Associate Professor, [2]M.V.Sc. Student; Department of Veterinary Surgery and Radiology; College of Veterinary Science & Animal Husbandry; Orissa University of Agriculture and Technology, Bhubaneswar-751003 (Odisha).
[Received: 08.3.2017; Accepted: 12.9.2017]

One Doberman and another Labrador female dogs were presented with the complaint of swelling at the perineal region extending to vulva. In one case, there was heavy swelling with ulceration of exposed part of the mass and in the second case there was gradual increase in size of the mass beneath the skin. Physical and radiographic examinations confirmed as cases of tumor like mass in both the cases. Under physical restraint and general anaesthesia, excision of the tumor mass was done. Histologically, both the cases were diagnosed as leiomyoma. Both the cases recovered well without any complicated symptoms thereof up to one year after surgery.
Key words: Dog, Surgical management, Vulvo-vaginal leiomyoma.

Tumors of female reproductive tract are divided into two categories: viz. the growths that are arising from ovaries and those derived from the tubular genitalia in dogs (Susaneck, 1981). Neoplasms of female tubular genitalia account for 3% of all canine tumors; of these 85-90% occurs inside vagina and vulval regions. Tumors of mesenchymal origin: leiomyomas, fibro-leiomyomas and fibromas occur most commonly in dogs. Leiomyomas are common in the canine female reproductive tract and account for 2.4% of all canine neoplasms. About 85% of leiomyomas occurring in the reproductive tract of bitch arise from vagina, vestibule and vulva. In bitch, these are frequently associated with estrogen secreting tumors or ovarian follicular cysts (Susaneck, 1981).

Vaginal leiomyomas may be single or multiple, intraluminal or extraluminal in position. The tumor is usually seen as round or oval, well defined and encapsulated. Their size and consistency may also vary depending upon their duration of growth and then becomes firmer due to increase in connective tissue. Large intraluminal tumors may protrude through vulva, while extraluminal tumors tend to cause perineal swelling. At this stage the tumor may impinge upon urethra and rectum causing animal to show signs of dysuria, constipation and tenesmus. Treatment procedures and prognosis vary considerably of these conditions. The genital tract tumours are usually seen in medium-aged non-spayed dogs and the recommended choice of treatment is the surgical management (Klein, 2006). Surgical resection of neoplastic tissue was also recommended as a treatment choice in benign vaginal tumours (Sontaş *et al.*, 2010). As they have a good prognosis with a mean survival time of 18 months, if the tumour is excised entirely (Thatcher and Bradley 2005). Local treatment of vaginal leiomyomas primarily involves surgical excision of the mass (Susaneck, 1981). The hormonal influence on the growth of vulvar/vaginal tumours has been reported by MacLachlan and Kennedy (2010). Since the canine genital tract leiomyomas are reported as having high progesterone receptors so after the mass reduced in size by using aglepristone, then it was removed surgically (Millan *et al.*, 2007). The prognosis for vaginal leiomyomas is good as they are benign.

In the present paper two cases of vulvo-vaginal leiomyomas and their successful treatment in a two year old female Labrador and 5 year old Doberman bitches were reported.

Materials and Methods

Case no. -I

A two year female Labrador dog was presented with a large swelling at the inner aspect of vulva with ulceration due to heavily exposed outside with complaints of fever, dysuria, constipation and inappetance. Physical examination revealed a non fluctuating mass at the upper part of vagina without any stump and the exposed mass was

ulcerated. Radiographic examination revealed radio dense mass at the region. The condition was tentatively diagnosed as a neoplastic growth, so decision of surgical excision was taken to relieve pain and sufferings of the animal. The owner was advised to keep the animal in fasting for 18 hours. The animal was administered with ceftriaxone sodium @10 mg/kg b.wt. I/M and meloxicam @ 0.02 mg/kg b.wt. I/M as preemptive analgesia. It was restrained and anaesthetized using atropine @ 0.04 mg/kg b.wt. I/M, xylazine @ 0.5 mg/kg b.wt. I/M and ketamine @ 3mg/kg b.wt. I/V with the fluid therapy. The site was routinely prepared for surgery. The sterilized artificial insemination catheter was placed at the urethral passage to keep the patency of urethra and act as a guide to prevent untoward complications. The mass was exposed after episiotomy and excised out. Bleeding was controlled with gauge pressure. Further per-vaginal assessments of the reproductive tract revealed multiple masses around the inner wall of vulva (Fig.1) and were excised out (Fig.2). The wound on the vaginal wall was sutured with Vicryl no. 2/0 suture in continuous pattern. The episiotomy wound was apposed by suturing the skin with underlying muscles and inner mucous membrane with nylon in simple interrupted pattern. Dressed the suture line with povidone iodine solution and Mupirocin ointment. Post operative ceftriaxone sodium @10 mg/kg b.wt. I/M and meloxicam @ 0.02 mg/kg b.wt. I/M were administered intramuscularly(IM) consecutively for five days.

Fig. 1: Multiple small masses in vulva

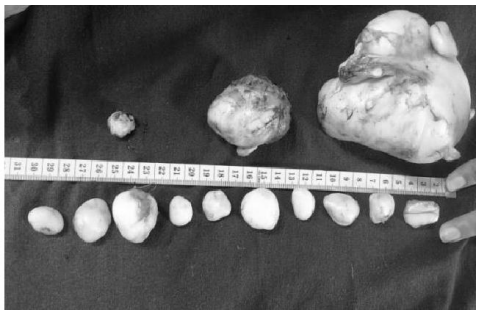

Fig. 2: Extracted Tumour masses

Case no.-2

A five year old female Doberman dog was presented with complaint of a large pendulous growth on the dorsal region of vulva along with anorexia, discomfort, dullness and problems in mating. The radiographic study revealed radio-dense/opaque mass at the site. The mass was not fluctuating and fine needle aspiration revealed no fluid inside it. Hence the condition was suspected for any neoplastic growth/ tumour. It was also managaed surgically by above discussed procedure. In addition to above, in this case the pendulous mass was exposed and seen without any stump. Blood vessels supplied to the stump were ligated and the growth was excised (Fig-3).

Fig. 3: Excision of the big tumour mass after episiotomy

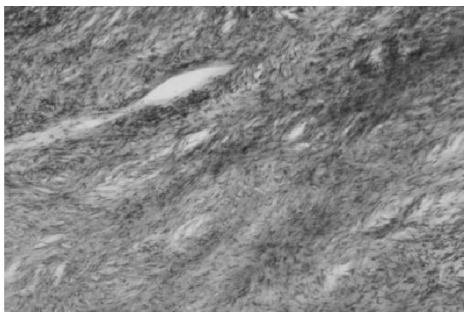

Fig. 4: Smooth muscle fibers in Histopathology

Results and Discussion

The bitches did not develop postoperative complications such as urine retention or incontinence. Histopathology of the mass revealed connective tissue coating covered by a thin layer of stratified epithelium. The tumor cells were of smooth muscle origin, lying in parallel bundles with interposed collagen fibers (Fig.4). These were diagnosed as cases of leiomyoma and the owners were advised for spaying their dogs in order to prevent recurrence of the tumor mass. The animals were followed up for one year after surgery and problems associated with tumor were not observed.

In the presented reported cases as it was difficult to exteriorise the tumour, hence episiotomy was performed. Latrogenic damage to the urethra or accidental injuries to other perineal structures are possible surgical complications. Urethral catheterization will greatly assist in avoiding damage to these structures. Postoperative infection and/or scar contracture can also result in urethral obstruction. While some authors believe that excision of the vaginal leiomyoma is curative, the condition will usually recur due to hormonal (i.e. estrogenic) influence. But in the present cases no such reoccurrence occurred even after one year.

References

Klein, M.K. (2001). Tumours of the female reproductive system. *In:* Withrow SJ and MacEwen EG (Eds), Small Animal Oncology. 3rd edn.. WB Saunders, Philadelphia, U.S.A., Pp. 445-454.

MacLachlan, N.J. and Kennedy, P.C. (2002). Tumors of the genital system, in: Meuten DJ (Eds), Tumors in domestic animals. 4th edn., Iowa State University Press, Ames, IA, Iowa, U.S.A. Pp. 547-573.

Millan Y, Gordon, A., De Los Monteros,A.E., Reymundo, C. and Martin De Las Mulas, J. (2007). Steroid receptors in canine and human female genital tract tumours with smooth muscle differentiation. *J. Comp. Pathol.*, **136**: 197-201.

Sontaş, B.H., Altun, E.D., Guvenc, K, Arun, S.S. and Ekici, H. (2010). Vaginal neurofi -broma in a hysterectomized poodle dog. *Reprod. Domes. Anim.*, **45**: 1130-1133.

Susaneck, S.J. (1981). Tumors of the female reproductive tract. *In:* Oncology notes. Fort Collins: Comparative Oncology Unit, Colorado State University, Colorado, U.S.A. Pp. 07-11.

Thatcher, C. and Bradley, R.L. (1983). Vulvar and vaginal tumours in the dog: a retrospective study. *J. Am. Vet. Med. Assoc.*, **183**: 690-692.