HEPATOID GLAND ADENOMA IN TWO DOGS: A CASE REPORT

Ganesh K. Sawale[1], Yash Suresh Savla, V.N. Dave, Ashlesha Dave-Satpute, Rajesh Rohi, D.S. Gavhane, V.S. Dhaygude and S.D. Moregaonkar[2]

Assistant Professor[1], Associate Professor[2], Department of Veterinary Pathology; Bombay Veterinary College, MAFSU, Mumbai-400065 (India).

[Received: 18.1.2017; Accepted: 10.10.2017]

Present communication reports two cases of Hepatoid gland adenoma presented for histopathological opinion to the department. Grossly, single circular growth of 5.5 x7x4 cm in diameter was present at the base of tail in an 8 year-old male Labrador cross. Whereas, the other case was in adult female non-descript dog with perianal nodular mass of 440 gm and size of 13.5x12 cm in diameter. Both the cases were diagnosed as that of Hepatoid gland adenoma.

Key words: Dog, Hepatoid gland adenoma, Histopathology.

Hepatoid Gland adenoma is a benign tumour that arises from modified sebaceous glands that are most abundant in the cutaneous tissues of perianal region ands on dorsal and ventral aspects of tail (Goldschmidt andHendrick, 2002 and Villalobos, 2011). Its occurrence is rare in female and castrated male. Hyperplasia and adenoma of Hepatoid gland is very common in intact male than female dogs as androgens stimulate the development of hepatoid gland leading to proliferative changes (Villalobos, 2011) English Bulldog, Beagle, German Shepherd Siberian Huskies, Samoyeds, Pekingese, and Cocker Spaniels are most commonly affected(Baba and Toi, 2007 and Villalobos, 2011). Present communication reports two cases of Hepatoid gland adenoma in dogs.

A circular growth of 5.5x7x4 cm in diameter size surgically removed from an 8-year-old male Labrador cross breed dog (Case 1; Fig.1) and another growthof 440 gm and size of 13.5x12 cm in diameter from perianal region of adult female non-descript dog (Case 2) were presented to the Department of Veterinary Pathology for histopathological opinion. On cutting, the growth was pale-brown in the first case and grey-white in the second case. The growth was firm in consistency in both the cases. The tissues from multiple sites from both the cases were collected in formalin and processed for paraffin embedded sectioning.

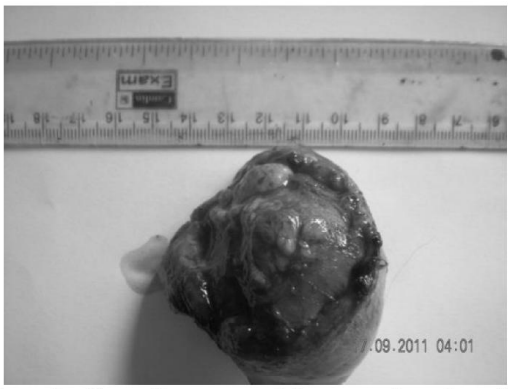

Fig.1: Case 1--Growth removed from perianal region

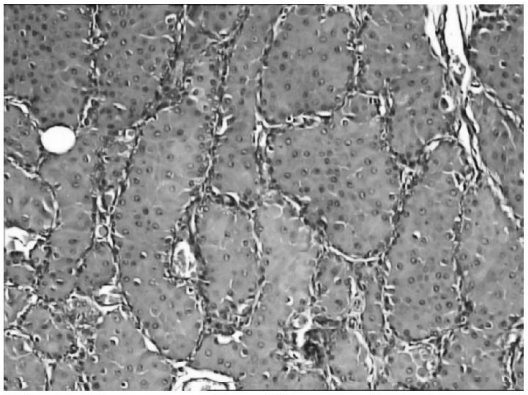

Fig.2: Tumour cells with round nucleus and moderate amount of eosinophilic cytoplasm resembling hepatocytes (H & E, 200X)

On the basis of histological evaluation, both the tumours were diagnosed as Hepatoid gland adenomas. Goldschmidt and Hendrick (2002) reported that the Hepatoid gland tumours can be soilitary or multiple with the size ranging from 0.5 cm to

5 cm in diameter and are pale brown on cut section. The tumour observed in 8 year male Labrador dog was similar to that in the previous studies (Baba and Toi, 2007 and Villalobos, 2011). Microscopic examination of tumor growth in both the cases showed tumour cells arranged in sheets/lobules that were separated by a thin stroma and surrounded by a capsule (Fig.2). The microscopic lesions described in the present investigation corroborate the findings of Goldschmidt, and Hendrick (2002), Trangadiya*et al.*, (2014) and Devi *et al.* (2012). The tumour growth was removed surgically and the male dog was castrated after diagnosis of the tumour. Villalobos (2011) also reported that up to 95% of male dogs suffering from hepatoid gland tumours respond favourably to castration and regress.

References

Baba, A.I. and Toi, C.C. (2007). Perianal gland tumours. *In:* Comparative Oncology. 1st edn., The Publishing House of the Romanian Academy, Bucharest, Bucuresti România. Pp. 85-91.

Devi, L.G., Chaudhary, A., Singh, N.D., Banga, H.S. and Gadhave, P.D. (2012). An incidental case of perianal gland adenoma in a stray dog. *Scientific J. Anim. Sci.*, **1**: 71-74.

Goldschmidt, M.H. and Hendrick, M.J. (2002). Tumors of the skin and soft tissue. *In:*Tumors in domestic animals. Meuten D.J. (edit.), 4th edn., Iowa State Press, Iowa, U.S.A. Pp. 68.

Villalobos, Alice E. (2011). Tumours of skin and soft tissues. *In:* The Merck Veterinary Manual 10th edn., 2nd Print; Merck & Co., Inc., Kenilworth, NJ, U.S.A. Pp. 666-680.

Trangadiya, B.J., Patel, J.M., Vihol, P.D., Prasad, M.C., Suthar, D.N. and Tyagi, S.K. (2014). Pathology of perianal tumours in dogs. *Indian J. Vet. Pathol.*, **38**(2): 122-123.

LIFE MEMBERSHIP

Membership of the Society is open to Veterinary / Medical Graduates who are actively engaged in the field of Canine Practice. For the membership, please write to **Prof. (Dr.) A.K. Srivastava,** Secretary General or **Dr. Shrish Chandra,** Treasurer, Indian Society for Advancement of Canine Practice, 21/5, Sector-21, Indira Nagar, Lucknow – 226 016 (U.P.) India.

You may download the Form from our website: www.isacp.in

The Life Membership Fee is Rs.1000.00 / $ 25/ £ 18.