MEIBOMIAN GLAND ADENOMA IN A DOG – A CASE REPORT

Ramya Boinepally[1] and Lakshman Mekala[2]
[1]Assistant Professor, [2]Professor, Department of Veterinary Pathology; College of Veterinary Science; PVNRT Veterinary University, Rajendranagar, Hyderabad-500 030 (Telangana).
[Received: 11.5.2017; Accepted: 27.11.2017]

A six year old German shephard dog was presented to TVCC, C.V.Sc, Hyderabad, with conjunctivitis, mild blepharitis and a visible growth on the right eye lid. On incision, it was hard to cut and grey white in colour. Histopathological examination of growth showed proliferation of glandular epithelium separated by connective tissue stroma. Focal haemorrhages and lymphocytic infilteration was also observed. The case was diagnosed as meibomian gland adenoma.
Key words: Blepharitis, Conjuctivitis, Meibomian gland.

Meibomian glands are modified sebaceous glands, located on the inner surface of the eye. It is classified as a tumor of the sebaceous meibomian sweat glands that line the upper and lower eyelids. Meibomian glands are sebaceous glands on the edge of the dog's eyelid (Gelatt, 1975). Their function is supplying sebum, or oil, to the eye. That sebum prevents evaporation of tear film over the cornea. Also known as a chalazion, a meibomian adenoma is a benign type of tumor growing out of the gland. It doesn't hurt, but it can ulcerate. That ulceration and tumor growth can lead to issues with the dog's cornea and conjunctiva. Meibomian glands are also known as tarsal glands. Tarsal gland adenoma (meibomian gland adenomas) are a common ophthalmological tumour of older dogs (Grahn, 2004), they don't metastasize to other parts of the body. Dogs between 8-13 years are at an increased risk and the breeds that are genetically predisposed include English Cocker Spaniel, Cocker Spaniel, Samoyed, Siberian Husky, Cairn Terrier, Dachshund, Minianture Poodle, Toy Poodle, Shih Tzu, Basset Hounds,Beagles and Kerry Blue Terriers. However, no sex predilection has been reported so far. This condition is more prevalent in dogs with hypothyroidism and can cause irritation by both mechanically contacting cornea as well as secreting unusual (Grahn and Sandmeyer, 2009).

A six years old German shepherd dog was presented to TVCC, College of Veterinary & Animal Science, Hyderabad, with conjunctivitis, mild blepharitis and a visible growth on the right eye lid. On observartion it was found that the dog was unable to see properly with right eye. The eyelids were adhered together. A tissue biopsy of the tumour was made and the tissue collected preserved in 10% buffered formalin for histopathological studies. The small representative pieces of fixed tissues were cut, washed, processed and paraffin embeded as per standard method. The paraffin block's sections were cut at 4 micron thickness by microtome and were stained by routine Hematoxylin and Eosin (H and E) stain and the stained sections were mounted with DPX mountant and kept ready for microscopic examination.

Histopathological examination revealed that tumor was composed of a solid growth of irregular islands and trabeculae of basaloid reserve cells, interspersed with fewer sebocytes. The basaloid cells showed moderate mitotic activity; predominantly active mitotic generative cells of sebaceous glands. Single cells showed lipid vacuoles representing the start of differentiation foci with squamous epithelium and keratinization, which represented areas of differentiation towards sebaceous gland structure (Fig.1). It was diagnosed as Meibomian gland adenoma.

Histopathological lessions are identical to those described for sebaceous adenoma. It was also observed that overlying epidermis is often hyperplastic and may be papillomatous and secondary inflammation is common. Severe granulomatous response with multinucleated giant cells occurs when there has been rupture of the tumor and release of sebaceous secretion into surrounding stroma

tendency to be highly melanizes, so must be differentiated from melanocytomas arising from this site; simillar findings have been reported by Romkes *et al.* (2014) also.

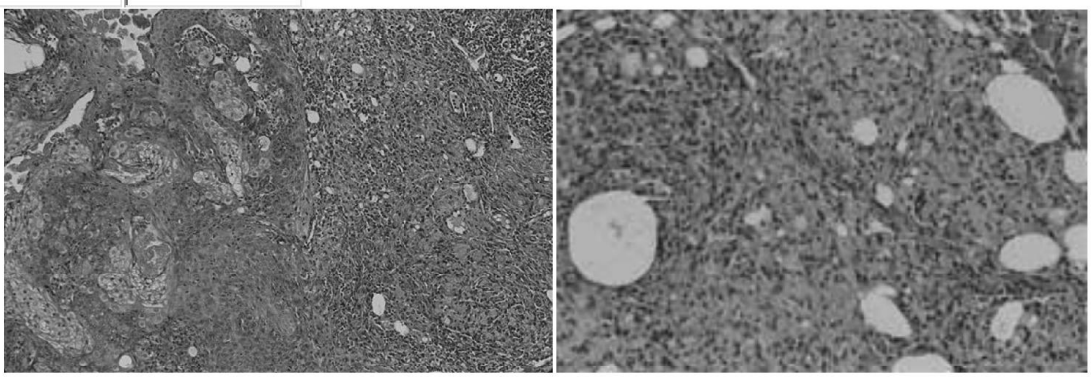

Fig. 1. Histopathologyrevealed that tumor was composed of a solid growth of irregular islands and trabeculae of basaloid reserve cells, interspersed with fewer sebocytes. Single cells showed lipid vacuoles representing the start of differentiation foci with squamous epithelium and keratinization, which represented areas of differentiation towards sebaceous gland (H&E).

These adenomas are slow growing and non-pigmented; extend out of the tarsal glands most commonly at the duct at the eyelid margin. The tumor itself is quite friable and it often overlies the eyelid margin. Occasionally they will grow under the palpebral conjunctiva and remain under the eyelid and do not extend out along the tarsal gland duct as also reported by Wilcock (1989). These tumors can become so large and rub so excessively on the cornea that they can cause an ulcer to develop on the surface of the cornea.

References

Grahn, B.H. (2004). Veterinary Ophthalmology Essentials. 3rd edn., Oxford: Butterworth -Heinemann , Philadelphia, Pennsylvania, U.S.A. Pp:35–65.

Gelatt, K.N. (1975). Meibomian adenoma in a dog. *Vet. Med. Small Anim. Clin.*, **70**(8): 962.

Grahn, B.H. and Sandmeyer, L.S. (2009). Diagnostic ophthalmology. Tarsal gland adenoma. *Can. Vet. J.*, **50**(11): 1199-2000.

Romkes, G., Klopfleisch, R. and Eule, J.C. (2014). Evaluation of one- vs. two-layered closure after wedge excision of 43 eyelid tumors in dogs. *Vet. Ophthalmol.*, 17(1): 32-40.

Wilcock, B.P (1989). Diseases of the eye and ear. *In:* Jubb KVF, Kennedy ,P.C., Palmer, N., (Eds.). Pathology of Domestic Animals. 3rd edn., WB Saunders, Toronto, Canada. Pp. 339–393.