DUCTAL CARCINOMA SIMPLEX IN A BITCH – A CASE REPORT

Ramya Boinepally[1] and Lakshman Mekala[2]
[1]Assistant Professor, [2]Professor, Department of Veterinary Pathology; College of Veterinary Science; PVNRT Veterinary University, Rajendranagar, Hyderabad-500 030 (Telangana).
[Received: 11.5.2017; Accepted: 28.11.2017]

A ten year old German shepherd female dog was brought to the TVCC, C.V.Sc., Hyderabad, with history of swelling, redness of mammary gland and bloody nipple discharge. Incised lump revealed grey white to grey brown areas and adipose tissue covering a mass. The area was ulcerating and a lactescent secretion with sanguinolent striations. Histopathological examination revealed the ducts are lined by a bilayered epithelium with foci of squamous differentiation and intracytoplasmic keratohyaline granules; round nuclei and prominent nucleoli. The case was diagnosed as ductal carcinoma simplex.
Key words: Carcinoma, Dog, Mammary gland.

Mammary gland tumors are frequent in dogs and cats but are uncommon in other domestic animals. In bitches, among all neoplasms, mammary tumors comprise 50%, of which approximately 60% are benign and 40% are malignant (Brearley, 1989). These are hormone dependent, and after each estrous cycle the risk of appearance increases. Mammary tumor cells have estrogen and progesterone receptors (Sobczak-Filipiak and Malicka, 2002). These hormones induce the hypertrophy of the mammary parenchyma, which is obvious after estrus (Moulton, 1978 and Brearley, 1989).

A ten year old German shepherd female dog was brought to the TVCC, College of Veterinary & Animal Science, Hyderabad, with history of swelling and redness at the mammary gland. The clinical symptoms observed are breast lump and bloody nipple discharge. Heamatology revealed leukocytosis, neutrophilia and mild anemia. On incision of the mass, section revealed grey white to grey brown areas and adipose tissue covering the mass. The area is ulcerating and a lactescent secretion with sanguinolent striations. The small representative tissue samples were collected in the 10% buffered formalin solution for histopathological studies. The formalin fixed tissues were processed and 3 to 5 μ thick tissue sections were prepared and stained with hematoxylin and eosin (H&E) stain following standard procedures. Histopathological examination revealed the ducts are lined by a bilayered epithelium with foci of squamous differentiation and intracytoplasmic keratohyaline granules; round nuclei and prominent nucleoli (Fig.1). On the basis of clinical and histopathological examination, the case was diagnosed as ductal carcinoma simplex.

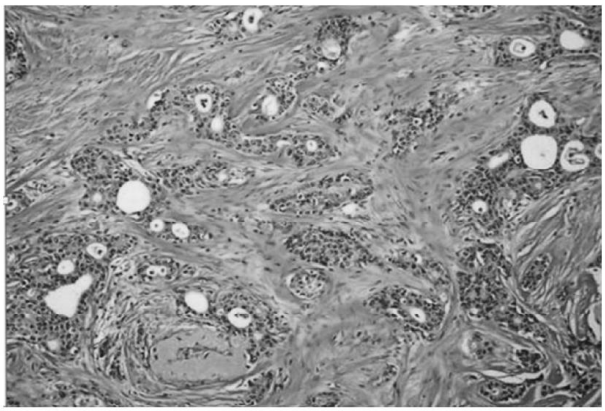

Figure.1. Ductal carcinoma of mammary gland. The ducts are lined by a bilayered epithelium with foci of squamous differentiation and intracytoplasmic keratohyaline granules(H&E).

Ductal carcinoma is a neoplasm that shows differentiation to interlobular ducts and is the malignant counterpart of the ductal adenoma. A simple carcinoma is composed of only one cell type, resembling either luminal epithelial cells or myoepithelial cells, simillar findings have been reported by Misdorp *et al.* (1972) and Misdorp *et al.* (1973). The neoplastic cell population is arranged in cords and tubules that surround slitlike lumina that are often lined by a double layer of epithelial cells that exhibit significant anisokaryosis and anisocytosis; there are also numerous mitotic figures. Focal or multifocal areas of squamous differentiation and keratinization are present, with intracytoplasmic keratohyaline granules within some cells also reported by Mitchell *et al.* (1974) and Abdel-fatah *et al.* (2007). The morphology of this neoplasm is identical to the apocrine ductal carcinoma of the skin as also reported by Goldschmidt *et al.* (2011).

It was concluded that the dog was suffering from ductal carcinoma simplex.

Rfereences

Abdel-fatah, T.M., Powe, D.G., Hodi, Z., Lee, A.H., Reis-Filho, J.S. and Ellis, I.O. (2007). High frequency of coexistence of columnar cell lesions, lobular neoplasia, and low grade ductal carcinoma in situ with invasive tubular carcinoma and invasive lobular carcinoma. *American J. Surg. Pathol.*, **31**(3): 417–426.

Brearley, M. J. (1989). Mammary gland tumours in the dog. Practice, 11(6): 248–253.

Goldschmidt, M., Pena, L., Rasotto, R. and Zappulli, V. (2011). Classification and Grading of Canine Mammary Tumors. *Vet. Pathol.*, **48**(1): 124.

Misdorp, W., Cotchin, E., Hampe, J.F., Jabara, A.G. and von Sandersleben, J. (1972). Canine malignant mammary tumours: II. Adenocarcinomas, solid carcinomas and spindle cell carcinomas. *Vet. Pathol.*, **9**: 447–470.

Misdorp, W., Cotchin, E., Hampe, J.F., Jabara, A.G. and von Sandersleben, J. (1973). Canine malignant mammary tumours: III. Special types of carcinomas, malignant mixed tumours. *Vet. Pathol.,* **10**: 241–256.

Mitchell, L., de la Iglesia, F.A., Wenkoff, M.S., van Dreumel, A.A. and Lumb, G. (1974). Mammary tumors in dogs: survey of clinical and pathological charecteristic-s. *Can. Vet. J.*, **15**(5): 131-138.

Moulton, J.E. (1978).Tumors in Domestic Animals. Tumors of the Mammary Gland, 2nd edn., University of California Press, Berkeley, Los Angeles, U.S.A. Pp. 346–371.

Sobczak-Filipiak, M. and Malicka, E. (2002). Estrogen receptors in canine mammary gland tumors. *Polish J. Vet. Sciences*, **5**: 1–5.