

SURGICAL MANAGEMENT OF A VAGINAL LEIOMYOMA IN A GERIATRIC NON DESCRIPT DOG

Manasa, M.¹ Sai Gunaranjan, K.² Jyothi, K.³ and Reshma, Sk.¹

¹M.V.Sc Student, ²Assistant Professor, ³Assistant Professor and Incharge, Department of Veterinary Gynaecology and Obstetrics, College of Veterinary Science Srivenkateswara Veterinary University, Proddatur, Andhra Pradesh..

DOI 10.29005/IJCP.2024.16.2.145-147}

[Received: 26.09.2024; Accepted: 26.10.2024]

How to cite this article: Manasa, M. , Sai, G.K., Jyothi, K. and Reshma, Sk., (2024). Surgical Management of A Vaginal Leiomyoma in A Geriatric Non descript Dog. Ind. J. Canine Pract., 16(2): 145-147.

Leiomyomas are benign smooth muscle tumour that can develop in the reproductive organs including vagina of dog. A 12 year old non descript female intact dog was presented to the clinic with the complaint of swelling of perineum and a mass protruding from the vulva since past one month. The mass was identified as the growth on per-vaginal examination and confirmed as leiomyoma by histopathology. The multiple tumours were excised surgically under general anaesthesia. Post-operative care was followed up with antibiotic and anti-inflammatory drugs for five days and animal recovered uneventfully without any recurrence.

Keywords: Benign tumour, Leiomyoma, Pervaginal examination, Post-operative care.

The dogs are susceptible to various reproductive disorders and one of them is leiomyoma. Tumours of the female reproductive tract account for 3% of all canine tumours, with 85-90% of these neoplasms being located in the vagina and vestibule (Bondinga *et al.*, 2019). Leiomyoma is a benign tumour that develops from the smooth muscle cells that may arise in any organ with connective tissue including reproductive tract but uterus and gastrointestinal tract are the most common sites (Singh *et al.*, 2014). Leiomyomas are seen to be having high incidence in middle aged dogs that are not spayed and recorded more in multiparous dogs (Lee *et al.*, 2014). Vaginal leiomyoma may be single or multiple, usually round or oval, intraluminal or extraluminal, well defined pedunculated and encapsulated mass. Tumours that are large and intra luminal can extend through the vulva, whereas tumours located outside the lumen typically result in swelling of the perineal area (Umamageswari *et al.*, 2016). Leiomyomas must be distinguished from leiomyosarcomas which are malignant through histological analysis and differentiated from hyperplasia, TVT, abscessation or granulation. The prognosis is

positive since the leiomyoma is classified as benign, which eliminates the possibility of metastatic spread. The present report represents the management of vaginal leiomyoma and its outcome.

Case History and Observations

A 12 year old non descript intact female dog was presented to the Veterinary Clinical Complex, College of Veterinary Science, Proddatur, with the complaint of a reddish mass protruding from the vulva (Fig 1) since past one month with occasional bleeding from vagina. The perineal swelling (Fig 2) of the dog between anus and vulva was also observed since one month and mild straining at the time of defecation reported, however micturition was normal. Upon per vaginal examination round, hard enlarged smooth surface of tumour masses were palpable. Several tumour growths were observed and that were extended cranially in the vagina. The animal was found to be dull with normal rectal temperature. The heart rate and respiratory function was normal. No bleeding from the mass was observed. The serum biochemical and hematological parameters were within normal range except mild lymphocytosis. The mass was diagnosed

tentatively as vaginal tumour after per-vaginal palpation and planned for surgical intervention.

Treatment

The dog was pre-anaesthetized with xylazine (@1.1mg/kg B.Wt) and atropine sulphate (@0.06mg/kgB.Wt) intra muscularly. The surgical procedure was performed under general anaesthesia using inj. Thiopental sodium @12.5mg/kg B.wt. The Perineal region of the animal was shaved and sterilized. A bandage was applied to the tail of the dog and tail was arched cranially over the spine. After all the pre-operative preparation, the animal was placed in sternal recumbency on the Operation table. The surgical incision was done between anus and vulva to expose the tumour masses. Tumour growths were embedded deeply (Fig 3) which can be defined as intraluminal growth with well-defined stalk. Small blood vessels were

clamped using artery forceps while large blood vessels were ligated. Multiple tumour growths of various size which were round to oval in shape were excised carefully by incising the capsule (Fig 4). The size of tumour growths varied between 1 to 12cm in diameter. All these growths were recovered from dorsal wall of vagina. The incision site was closed by opposing the vaginal mucosa using chromic cat gut. size 1-0 by following simple continuous suture pattern. The skin was closed routinely and the animal was administered with antibiotic Inj.Ceftriaxone with Tazobactam (@20mg/Kg B.wt) and Inj.Tramadol (@3mg/Kg B.wt) intravenously for 5 days. The animal recovered and sutures were removed after 10 days of surgery. No recurrence reported even after nine months. The samples of masses were sent for histopathology for further confirmation of tumour.

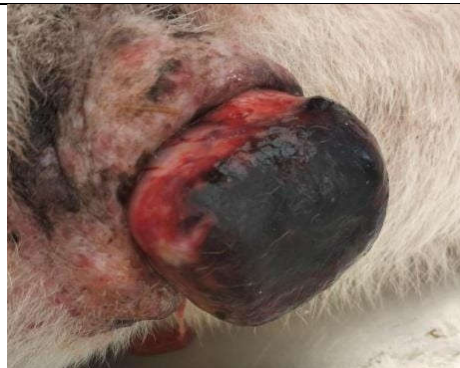

Fig.1: Reddish mass protruded from the vulva of female dog.

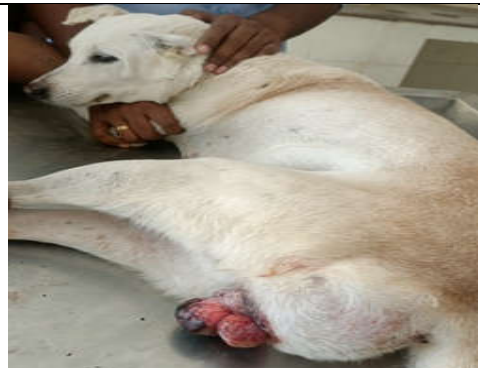

Fig.2 : Swelling of the perineal region of the bitch (Arrow).

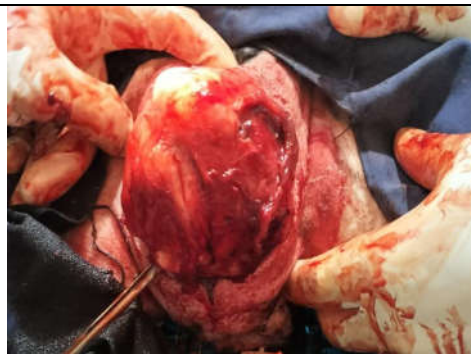


Fig.4: A large tumour mass encapsulated in vaginal wall.

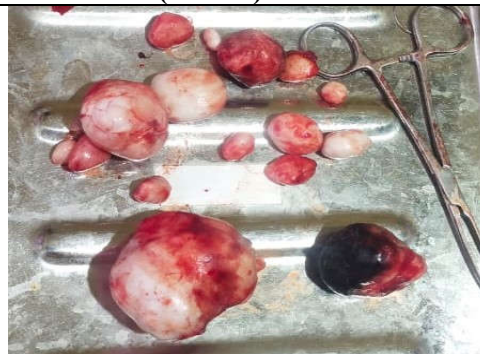

Fig.5: Tumour masses of various sizes removed after surgery

Results and Discussion

The surgical approach followed in the present case was in agreement with the authors Dey *et al.*, 2017, and Minu *et al.*, 2021. Episiotomy incision may be necessary for removing larger tumour mass as mentioned by Dey *et al.*, 2017, which was practiced in the present case also. Radiation therapy can be done if the mass cannot be excised surgically. Even though the tumour is excised completely the recurrence of leiomyoma occurs due to hormonal influence as also suggested by Bodinga *et al.*, 2019. However in the present case no recurrence was reported even after nine months which was in accordance with the findings of Saikia *et al.*, 2018. Generally leiomyoma's of the reproductive tract were associated with estrogen producing tumours, ovarian follicular cysts, cystic endometrial hyperplasia. Although the defined pathogenesis of vaginal leiomyoma by the estrogen is unclear Ovariohysterectomy can be considered to prevent recurrence as also recommended by Minu *et al.*, 2021. In the present case ovariohysterectomy was not carried out however recommended for the dog to the owner.

Conclusion

It can be concluded that vaginal leiomyomas can be excised successfully surgically with minimal risk of complications and surgical removal is typically curative.

References

Bodinga, H.A., Abubakar, N., Abdullahi, N.

- and Hassan, T. (2019). Vaginal leiomyoma in a crossbred Rottweiler female dog-a case report. *Asian Journal of Research in Animal and Veterinary Sciences*, **3**(3): 1-4.
- Dey, T., Das, B.C., Imran, S., Bostami, M.B., Sutradhar, B.C., and Poddar, S. (2017). Surgical management of canine vaginal leiomyoma of a bitch in saqtvh, Bangladesh. *Res. J. Vet. Pract.*, **5**(4): 40-43.
- Lee, S.H., Park, C.H., Park, J.T., Kim, Y.M., Oh, K.S. and Son, C.H. (2014). Extraluminal form of vaginal leiomyoma: Two case reports. *Journal of Veterinary Clinics*, **31**(6): 539-543.
- Minu, X., Abhilash, Jayakumar, R., Kumar, V. and Shabeeba, P. (2021). Surgical management of cystic endometrial hyperplasia-pyometra complex with uterine fibroadenoma and vaginal leiomyoma in a dog. *The Indian Journal of Animal Reproduction*, **42**(1): 58-60..
- Saikia, B., Bayan, H., Sarma, K., Talukdar, D., and Ahmed, F.A. (2018). Surgical management of vaginal leiomyoma in bitch. *Theriogenology*, **8**(3): 95-99.
- Singh, K., Bodh, D., Gopinathan, A., Mohsina, A., and Sangeetha, P. (2014). A case of concurrent inguinal hernia and vaginal leiomyoma in a bitch successfully treated surgically. *Res. J. Vet. Pract.*, **2**(1): 1-4.
- Umamageswari, J., Sridevi, P., Rangasamy, S., and Sridhar, R. (2016). Vaginal leiomyoma in a pregnant bitch. *The Indian Journal of Animal Reproduction*, **37**(2): 71-73.