

## SUCCESSFUL SURGICAL MANAGEMENT OF CYSTIC UROLITH IN A SHIH TZU DOG

Vani, G.<sup>1</sup>, Kamalakar, G.<sup>2</sup>, Devi Prasad, V.<sup>3</sup> and Mallikarjuna, Rao, Ch.<sup>4</sup>

<sup>1</sup>Associate Professor, <sup>2</sup>Assistant Professor, <sup>3</sup>Professor and Head, <sup>4</sup>Assistant Professor, Department of Veterinary Surgery, N.T.R. College of Veterinary Science, Sri Venkateswara Veterinary University, Gannavaram (Andhra Pradesh).

DOI 10.29005/IJCP.2024.16.2.159-162}

[Received: 19.10.2024; Accepted: 29.10.2024]

**How to cite this article:** Vani, G., Kamalakar, G., Prasad, D. and Rao, M. Ch. (2024). Successful Surgical Management of Cystic Urolith in A Shih tzu Dog, Ind. J. Canine Pract. 16(2): 159-162-.

A five-year-old female Shih tzu dog was presented with a history of anorexia, dullness, depression and haematuria. After physical and clinical examination, further investigations such as survey radiography, and ultrasonographic studies were undertaken. Based on history, clinical signs, physical and radiographic examination and ultrasonographic studies, it was confirmed as a case of cystourolith and performed caudal ventral celiotomy, followed by cystotomy and cystorrhaphy. With post-operative fluid therapy, antibiotics, analgesia and regular antiseptic wound dressing, the dog recovered uneventfully.

**Keywords:** Cystorrhaphy, Cystourolith, Shih tzu dog.

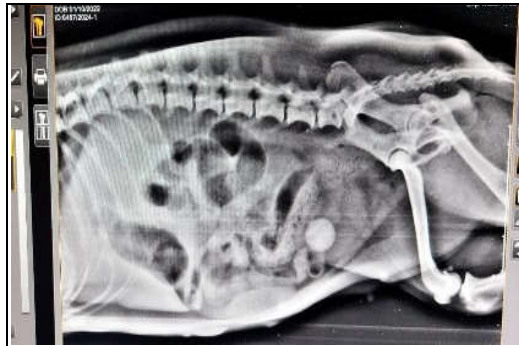Urolithiasis is a common cause of lower urinary tract disease in dogs and cats. Uroliths are collection of crystalline and non-crystalline solid particles that occur in one or more sites along the urinary tract. Uroliths are organized organic and inorganic solutes that precipitate around the nidus because of over saturated urine (Breshers and Confer, 2017), as these could interfere with complete and frequent urination. Oxalates are the most common canine cystoliths. The present case is the report of the management of cystic calculi in a dog through cystotomy.

### Case history and Observations

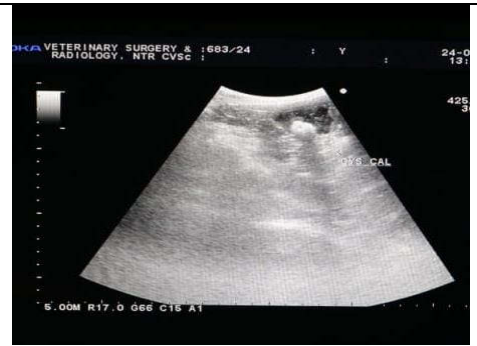A five-year-old Shih tzu bitch was presented to the small animal surgery unit of the Veterinary Clinical Complex, NTR CVSc, Gannavaram with a history of anorexia, dullness, depression and haematuria for the past three days. It was fed with family meals supplemented with bones and sometimes commercial pet food. The physical examination of the animal revealed normal

rectal temperature, heart rate and respiratory rate. Haematuria, urinary incontinence, abnormal urinating position, dysuria were the clinical findings observed.

Survey radiographic study (Fig. 1) of lateral view of abdomen showed a radiopaque oval calculus in the urinary bladder. Ultrasonography (Fig. 2) revealed hyperechoic focal echogenicity creating distal acoustic shadow in the dependant portion of the bladder confirming the presence of cystic calculus. Haematology of both the dogs revealed mild leucocytosis (17,000cells/cmm and 17500cells/cmm) and the DLC revealed with neutrophilia with 95% and 98% neutrophils and 6% and 7% lymphocytes. The serum biochemistry showed elevated BUN (78mg/dl and 80mg/dl) and Creatinine level (3.2mg/dl and 3.5mg/dl). Pooling up of all the diagnostic evidences like physical, chemical, radiographic, ultrasonographic, hematobiochemical parameters, the case was diagnosed as cystic urolithiasis and the surgical correction was planned.



**Figure 1** Lateral abdominal radiography showing radioopaque oval calculi in the urinary bladder



**Figure 2** hyper echoic structure in the bladder exhibiting an acoustic shadow below it, indicating cystic calculi

### Surgical Treatment

On the day of surgery, the dog was premedicated using Inj. atropine sulphate at the dose rate of 0.04 mg/kg body weight subcutaneously, half an hour before the induction of anesthesia. General anesthesia was induced using a combination of Inj. Midazolam at a dose rate of 0.2 mg/kg body weight and Inj. ketamine hydrochloride at a dose rate of 5 mg/kg body weight administered intravenously mixed in a single syringe. After induction, the dog was intubated with endotracheal tube of suitable size and the cuff was inflated. General anesthesia was maintained with 2% - 3% of Isoflurane mixed in oxygen administered through circle system of small animal anesthetic machine. The dog was placed in dorsal recumbency and the site of surgery was aseptically prepared. Caudal ventral celiotomy was performed and the urinary bladder engorged with serosal blood vessels was located and brought to the surgical site (Fig. 3). After proper packing with surgical sponges, a nick incision was made on the urinary bladder, at the least vascular area and the calculus was removed (Fig. 4). After flushing the bladder with normal saline, cystorrhaphy was done with 2-0 vicryl by double layer Cushing pattern and the bladder was repositioned. The abdominal cavity was flushed with normal saline and the surgical incision was closed with vicryl (1-0) with simple interrupted sutures. This is followed

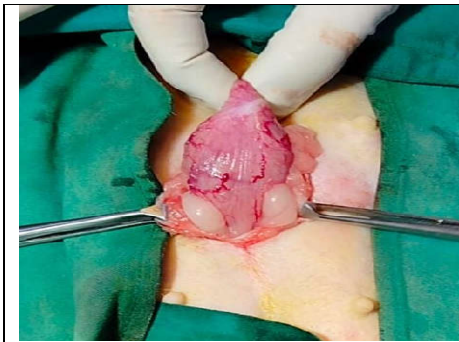
by subcutaneous and skin sutures. Postoperatively the dog was administered with inj. RL @ 10 ml/kg. bt intravenously, inj. Ceftriaxone @ 20 mg/kg. bt intravenously, inj. melonex @ 0.2mg/kg. bwt., subcutaneously. Vital signs like heart rate, respiratory rate and rectal temperature were monitored throughout the surgery. The wound dressings and case was regularly monitored for 2 weeks for any abdominal distension / wound dehiscence and the owner was advised to restrict the dog movement. The dog showed remarkable progress and the wound healed without any complications and skin sutures were removed on the 14<sup>th</sup> postoperative day.

### Results and Discussion

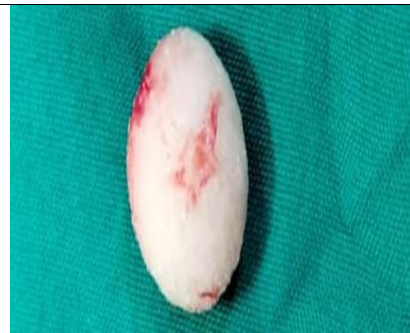Contrary to the human being, the kidney is not the common site for lodgement of calculus in dog, as about 95% of calculi in dog are found either in the bladder or urethra and bladder together as also reported by Uma *et al.*, 2018. The most frequent anatomical location of calculi in male is urethra followed by urinary bladder, however calculi in females are usually located in the urinary bladder. The symptoms like haematuria and dysuria exhibited by the dog might be due to irritation of bladder mucosa by the urolith as also mentioned by Rana *et al.*, 2022. Increased level of BUN and Creatinine may be attributed to prolonged retention of urine. Elevated creatinine level could be due to renal damage caused by hydrostatic pressure

on the kidney and increased reabsorption of creatinine from bladder due to prolonged stasis of urine in the urinary bladder. The present case was easily diagnosed by radiography and ultrasonography. The interpretation of radiographic image, as the

presence of radiopaque cystic calculi was very helpful in diagnosing the cystic calculi. Similarly Kokila *et al.*, 2023 also successfully managed cystic urethral calculi in a 6-yr old male mongrel dog with cystostomy and urethrotomy.



**Figure 3** Urinary bladder with engorged serosal blood vessels



**Figure 4** Large oval cystolith with surface porosity

Infrequent urination as a result of confinement, lack of regular exercise, urine retention for more than 24 hrs, becomes alkaline due to release of ammonia from breakdown of urea. Reduced water intake, high levels of minerals in diet and excess protein may also contribute to the disease. Dogs must be fed with diets that lower urinary phosphate and magnesium and maintain acidic urine as also recorded by Uma *et al.*, 2018. In this case, there was no reoccurrence for a period of 6 months. Following surgical intervention proper general and dietary management is required to prevent reoccurrence of cystolith as also recommended by Uma *et al.*, 2018. In the present cases, the biochemical analysis of the cystic calculus by Fourier Transform Infrared Spectroscopy (FTIR) revealed that it was made up of calcium oxalate salts. In the present case, the biochemical analysis of the cystic calculi in both the cases revealed that it was made up of calcium oxalate salts which may be due to usage of hard water by both the bitches. The incidence of obstructive urethral urolithiasis was more common in adult castrated male dogs where as cystic calculi was more common in female dogs as also reported by Njoku *et al.*, 2021. Older dogs

had higher susceptibility than young animals as also mentioned by Formsa and Saini, 2019. Surgical interventions such as cystostomy, urethrostomy and nephrotomy comprises incisional removal of calculi from the urogenital tract.

### Conclusion

The timely diagnosis and appropriate veterinary intervention will save the life of the animal. Among the available treatment options surgical treatments along with post operative management will give satisfactory results. Diet modification will prevent recurrence.

### References

- Breshers, M.A. and Confer, A.W. (2017). The urinary System. *Pathol. Basis Vet. Dis.*, C.I: 617-681.
- Formsa, A. and Saini, N.S. (2019). Canine urolithiasis and concurrent urinary bladder abnormalities: symptoms, haematology, urinalysis and comparative radiographic and ultrasonographic diagnosis. *Veterinary Medicine Open Journal.*, 4(1):18-26.
- Kokila, S., Manjuriya, R., Aruneshwaran, E.L., Kandaswamy, S., Sankar, P., Vijaya

- Kumar, M., Kumaresan, A. and Kathirvel, S. (2023). Successful surgical management of cystic and urethral calculi in a dog: A Case report *The Pharma innovation Journal*, **12**(8): 1069-1071.
- Njoku, N.U., Ajayi, N.O., Kalu, N.R. and Ukwani, C.P. (2021). Management of canine urolithiasis by cystotomy in a two-year old Lhasa Apso bitch, *J. of Sustainable Veterinary & Allied Sciences*, **1**(1):96-99.
- Rana, C., Subedi, D., Kunwar, S., Neupane, R., Shrestha, B., Sharun, K., Singh, D.K. and Kaphle, K. (2022). Cystic Urolithiasis in Dogs: A Case Report and Review of Literature *Veterinary Science Research and Reviews*, **8**(1): 1-7.
- Uma, S., Kumar, R., Lakkawar, A.W. and Nair, M.G. (2018). Cystolith in a dog: A case report. *Journal of Entomology and Zoology Studies*, **6**(1): 924-926.