

INTESTINAL OBSTRUCTION DUE TO ADENOMA A DOG

H.T. Jain¹, S.V. Upadhye², V.M. Dhoot³, Gauri Khante⁴ and Vaishali D.Chipde⁵

¹Veterinary Surgeon and Private Practitioner, ²Veterinary Surgeon, TVCC, ³Veterinary Physician, TVCC, ⁴Veterinary Surgeon, SMS, ⁵Veterinary Physician, Nagpur Veterinary College, Nagpur, Maharashtra

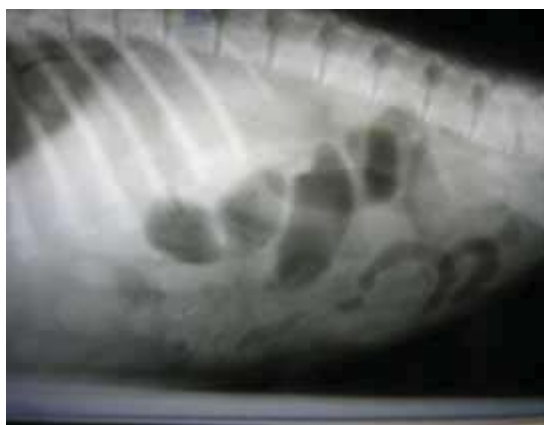Tumour of the small intestines are very rare in canine. They constitute only 1 percent of the total gastrointestinal neoplasms (Gore *et al*, 2006). Clinically, they may result in chronic vomiting, diarrhoea, weight loss and may even obstruct the intestinal lumen partially or completely, if are of larger size. A case of adenoma causing complete obstruction of the small intestine in a Labrador dog is reported.

Case History and Clinical signs:

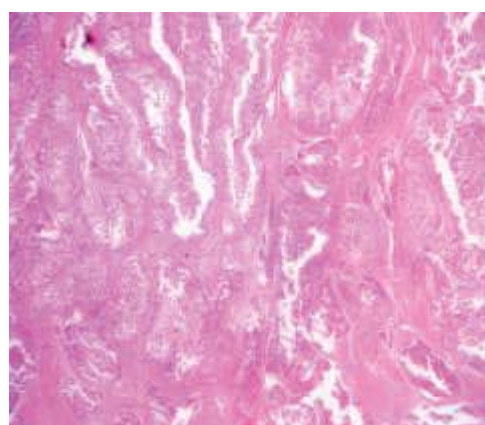
A twelve year old Labrador male dog was presented with the history of chronic but infrequent vomiting over a period of about two months, the frequency being increased since last 8 to 10 days. The dog earlier had hard blood tinged faeces for aqbout ten days and was unable to pass stools for four days. The

clinical parameters viz. temperature, pulse and respiration were within the normal limits. The examination also revealed severe dehydration and cachexia. Palpation of abdomen revealed a hard lump of about 3 inches in diameters in the mid abdominal area. Plain lateral radiograph of lateral abdomen revealed gas filled loops anterior to the suspected site of lump (Fig.1). However, thoracic radiograph did not reveal any pathology. The lump, however, could not be seen radiographically. Hematobiochemical studies revealed leucocytosis with neutrophilia. The BUN level was within normal limit (15 mg/dl) but the serum creatinine value was elevated (2.8 mg/dl).

It was decided to perform the exploratory laparotomy as there was complete intestinal obstruction.



Fig[1].Gas filled intestinal loops



Fig[2].Adenoma of intestine

Surgical Procedure:

The dog was given supportive treatment on the day of report with intravenous infusion with DNS and Ringers lactate and inj. Ceftriazone 500 mg along with inj. Metronidazole 100 ml intravenously. The surgical intervention was scheduled on the next day. The dog was sedated with Diazepam @ 1 mg/kg body weight I/V and premedicated with Atropine sulphate and Betnesol. Surgery was performed under dissociative anaesthesia with Ketamine hydrochloride @10 mg/kg body weight intravenously. The laparotomy was performed and the intestinal loops were exteriorized and examined for the pathology. The portion of the jejunum with soft swelling

was observed. Palpation of the swelling revealed intraluminal lesion. However, an incision over the lesion revealed severely thickened intestinal wall for about three inches in width and three inches in length. The enterectomy was performed to dissect out the neoplastic mass. The mesenteric lymph nodes were examined for any metastatic lesions. However, all the lymph nodes were normal in size. The intestinal anastomosis was performed with end to end technique at the healthy portion by placing double row of Lambert sutures. Patency of the intestine at the suture line was ascertained. Abdominal incision was closed in routine manner. Post-operatively inj. Ceftriaxone 500 mg and metronidazole 75 ml

by intravenous route was given twice a day for 5 days and inj. Meloxicam 10 mg was given intramuscularly for 3 days. The dog was maintained on intravenous fluid therapy for five days and thereafter owner was advised to feed the dog with soft semisolid diet for next 1 week. The patient responded well to the treatment and was reported to be normal in a month. The histopathological studies confirmed the mass to be the adenoma (Fig. 2).

Discussion:

The gastrointestinal obstructions due to various reasons are common in dogs. They include vomiting, diarrhoea with or without blood stained stools, or constipation, straining for defecation, varying degrees of dehydration and cachexia. The small intestinal neoplasia is uncommon in dogs, occurring with less frequency than tumours of the large intestine (Birchard, 1986). Signs in the dog with gastrointestinal neoplasia are often associated with neutrophilic leukocytosis, anaemia of varying degree and normal and slightly increased BUN content (Kolaja, and Fairchild, 1973). The leucocytosis with neutrophilia was also recorded in the present case along with increased serum creatinine value. However, serum urea level was within the normal limit. Radiograph of the thorax may be considered important for evaluating the full extent of disease in a patient. However, there was no detectable radiographic changes in thorax. Patnaik *et al* (1977) studied 119 dogs with gastrointestinal neoplasms and reported leiomyosarcoma to be the most common malignancy of small intestines. Adenomas are rare in small intestine (Bagley, 1996). The

resection of the affected intestinal loop was performed to maintain the patent lumen of the intestinal tract. Martin and Gagnon (2006) reported surgical resection of a gastrointestinal stromal cell tumor by double enterectomy and partial pancreatectomy on a 13-year-old mixed breed dog. The histopathology suggested the mass to be adenoma, a benign tumour. Hence, further treatment with chemotherapy was thought unnecessary. Enterectomy for removal of the affected intestine yielded desired results and the dog had normal activities for the follow-up period of about one year.

References:

- Bagley, R.S. (1996) Hypoglycemia associated with intra-abdominal leiomyoma and leiomyosarcoma in six dogs. *J Am Vet Med Assoc* **208**: 69.
- Birchard, S.J. (1986) Nonlymphoid intestinal neoplasia in 32 dogs and 14 cats. *J Am Anim Hosp Assoc*, **22**:533.
- Gore R. M., Mehta U. K., Berlin J.W., Rao V. and Newmark G.M. (2006) Diagnosis and staging of small bowel tumors. *Cancer Imaging* (6):209-12.
- Kolaja G.J., Fairchild D.G. (1973) Leiomyosarcoma of the duodenum in a dog. *J. Am. Vet. Med. Assoc.* (163):275-276.
- Martin I. And Gagnon A.M. (2006): Surgical resection of a gastrointestinal stromal cell tumor by double enterectomy and partial pancreatectomy on a 13-year-old mixed breed dog *Can. Vet. J.* **47**(4):370-373.
- Patnaik A. K. , Hurvit A. L. and Johnson G.F. (1977) Canine gastrointestinal neoplasms. *Vet. Pathol.* (14):547-555.

