

# A NEW TECHNIQUE FOR MANAGEMENT OF EXPERIMENTAL SPINAL CORD COMPRESSION IN DOGS

A.K. Srivastava and S.S. Misra\*

Surgery Department, Veterinary College, Mathura – 228 001, India.

Traumatic injuries to the spinal column in Dogs and Cats are frequently encountered in our day to day clinical practice. Different surgical techniques are available for the treatment of traumatic injuries of the spinal column. However, it is unfortunate that most of the Dogs and Cats with spinal injury in India get euthanized or die after suffering on their own without getting appropriate treatment. Spinal Cord compression due to various etiological factors is one of the important causes responsible for neurologic disturbances in dogs. Hence a new simple method for this purpose has been conducted successfully in this study.

**Key Words** Spinal Cord compression, Sensory perception, Balloon compression, Spastic motor paralysis, Foley catheter, Hemilaminectomy, Dogs.

## Introduction

Automobile accidents, falling from heights, attack by other animals (including human beings) and trauma by blunt falling objects are the main causes for such injuries (Shores *et al.*, 1990). Spinal trauma of sufficient magnitude to cause vertebral fractures, luxations / subluxations, traumatic disk extrusion, or dural tear usually results in spinal cord concussion, laceration, compression or distraction (Summers *et al.*, 1995). The severity of injury depends on the velocity, degree, and duration of the compressive / distractive force. The most common spinal injuries sustained following trauma are vertebral fractures, vertebral luxations or subluxations, vertebral fractures/luxations, traumatic disc herniations and spinal cord concussion (Wheeler and Sharp, 1994). Hoerlein (1953) reported that the incidence of spinal cord compression at a small animal clinic was 5-10%. Apart from the external causes of spinal cord trauma, acute injury can arise from internal factors including intervertebral disk disease (Seim, 1996) and congenital deformities such as atlantoaxial subluxation. Spontaneous spinal fractures attributable to severe osteopenia and hypocalcaemia have been reported in cats with nutritional secondary hyperparathyroidism (Tomsa *et al.*, 1999), while a dorsally displaced Salter-Harris type I fracture of the cranial portion of the fourth cervical vertebra with the endplate present in the vertebral canal has been described in an adult dog with congenital hypothyroidism (Lieb *et al.*, 1997).

plating can be used simultaneously to provide stronger fixation and greater stability of the injured site. The combination is the most resistant of all techniques against dorsoventral bending (Walter *et al.*, 1986). Modified segmental fixation combined with figure of "8" tension band wiring over the site of fracture as reported by Voss and Montovan (2004) is another effective method for stabilization of fractures and dislocations of the vertebral column. Metal and Bone Cement technique was first described using Steinmann pins placed through the vertebral bodies (Rouse and Miller, 1975; Blass and Seim, 1984). Pins and bone cement provide greater rotational stability and strength of all the techniques tested (Whaldron *et al.*, 1991) and these biomechanical properties can be improved by using screws instead of pins. Transilial pins were introduced by Dulisch and Nichols (1981) for the treatment of fractures and dislocations of the lumbosacral region.

In an attempt to study this malady by different methods of producing an experimental compression of the spinal cord and the functional disturbances produced thereby, various authors have evolved some techniques, (Allen, 1911; Tarlov *et al.*, 1953 and Gage and Hoerlein, 1968). Though precise, most of these procedures are clumsy and can not be undertaken routinely. Hence a new simple method for this purpose has been conducted successfully in this study.

## Materials & Methods

The experiment was performed on 15

Spinal plating and vertebral body

\* Former Professor & H.O.D. Surgery and Former Dean, COVAS, Mathura.

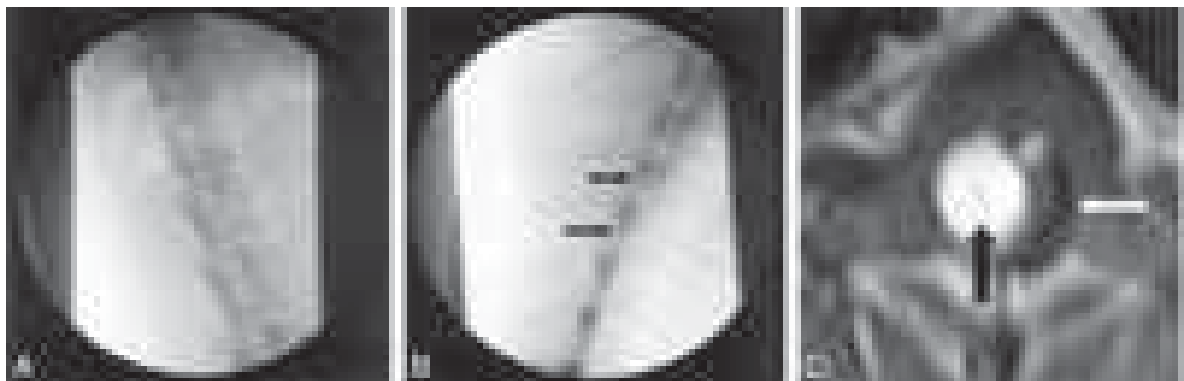
mature healthy dogs free from neurologic deficits. The animals were prepared for surgery in the routine manner.

The air from the balloon part of the Foley catheter to be used for the experiment was aspirated and replaced by 70% Sodium Iothalamate. The catheter thus loaded was immersed in 1% Polysan for 3 hours. It was washed with distilled water prior to use.

After anaesthesia with Thiopentone Sodium, a 12-15 cm. long skin incision was made at the dorsal midline with the third lumbar spinous process at its centre. The subcutaneous tissue was also divided at the midline and the lumbo-dorsal fascia to the left of the spinous process was incised, for 4-5 vertebral lengths. Then by a blunt dissection, the transversospinalis muscle was reflected away from the 2<sup>nd</sup> 3<sup>rd</sup> and 4<sup>th</sup> lumbar spinous processes. The blunt

dissection was continued until the entire arches of the three vertebrae up to the level of the transverse process were exposed, carefully avoiding the intervertebral artery and the nerves at the intervertebral foramina. The articular processes of the 2<sup>nd</sup> and 3<sup>rd</sup> lumbar vertebrae were then removed by using a pair of 3 mm mastoid bone rongeur.

Now by applying dorsal traction with the help of towel forceps affixed on the spinous process of the 2<sup>nd</sup> lumbar vertebrae, the interarcual space at the base of the spinous process was opened to allow the tips of the bone rongeur. A small piece of bone from the posterior rim of the lamina was thus removed, creating a small hemi-laminectomy opening. This opening was further enlarged as required, by removal of the lamina bone.



**FIG 1.** Images from a pilot study. After induction of general anesthesia, the lumbar subarachnoid space was entered with a needle. A guide wire was introduced via the needle and directed cephalad; then, the needle was withdrawn, and the guide wire was used for coaxial advancement of the angioplasty balloon, mimicking the method used in vascular access for angiography.

A, Guide wire introduced via neural foramen (lateral approach) and ascending in spinal canal.

B, Foley Catheter introduced over guide wire. Proximal and distal markers on balloon of catheter are shown by arrows.

C, Example of an MR image of a 7-mm balloon of Foley catheter (black arrow) inflated against the compressed spinal cord in dog (white arrow).

The Foley catheter was measured and marked by externally placing it against the tips of spinous process such that the balloon would be placed at the thoracolumbar junction. The lumbar subarachnoid space was entered with a needle. A guide wire was introduced via the needle and directed cephalad; then, the needle was withdrawn, and the guide wire was used for coaxial advancement of the Foley catheter, mimicking the method used in vascular

access for angiography. This Foley catheter was inserted into the vertebral canal to the prefixed mark. After converting the bony defect with a piece of absorbable gelatin sponge, the lumbo-dorsal fascia, subcutaneous tissue and the skin were sutured as per the routine process, maintaining the free end of the Foley catheter outside the wound. The catheter was fixed to the surrounding skin by a number of sutures. The wound

was covered with bandage and oral chloramphenicol and analgesic were given to the dogs.

On the next day, the dogs were tested and confirmed for absence of disturbed neurological functions which were then subjected to spinal cord compression. This was accomplished by a mechanical screw device to the distal broad end of the catheter there by inflating the balloon within the canal, which caused mechanical compression of the cord. This was continued until spastic motor paralysis occurred while retaining sensory perception.

### Results & Discussion

It was initially attempted to create compression by epidural injection of wax, shredded gelatin sponge, plaster of paris etc. However this method though non invasive, resulted into extremely variable compression due to diffuse spread of the agents. Custom made rubber balloons as used by Tarlov et al. (1953) and Gage and Horelein (1968) tended to have leaks and thus should not provide compression sufficiently long. The Foley catheter was more reliable in this regard. The drainage tube of the catheter that provided a direct communication to the exterior was plugged with a plastic stopper.

By using a liquid medium in the balloon of the catheter a more even distribution of pressure was achieved. Upon inflation of the balloon, the dogs exhibited signs of severe pain and discomfort, similar to that reported by Tarlov and Klinger (1954) loss of function in these dogs was exhibited as proprioceptive loss with in-coordination followed by loss of motor function and finally the loss of sensory perception. Tarlov & Klinger (1954) attributed this to the heavily myelinated larger fibre tracts conveying proprioceptive and motor impulses and which are more vulnerable to the effects of compression than the finer fiber tracts carrying sensory perceptions.

All the dogs showed spastic paraplegia post-compression which may be due to the damage of upper motor neuron pathways due to compression at thoracolumbar junction as reported by

Withrow (1974). In 3 dogs, sensorimotor paralysis exhibited immediately or within 24 hours was due to localized myelomalacia and fragmentation of the cord as seen at necropsy. This finding is similar to that of Tarlov & Klinger (1954) who postulated that the compression leads to complete mechanical distortion of the cord.

All the dogs under this study retained normal patellar, sciatic and withdrawal reflexes which could be because of intact lower motor neuron pathways. Five dogs exhibited Schiff-Schering-ton phenomenon. Chrisman (1982) remarked that acute trauma to the spinal cord between T2 and L3 result into this phenomenon because of release of ascending inhibition or the extensors of the fore limbs, from the lumbar spinal cord.

### Conclusions

It was concluded from the observation of this study that a controlled acute spinal cord compression can be obtained in the dogs with the help of very simple and commonly available Foley catheter like equipment, very successfully.

### References

- Allen, A.R. (1911). Surgery of Experimental lesion of spinal cord Equivalent to crush injury or fracture dislocation of spinal Column J.A.M.A., 57:878-880.
- Blass, C.E. and Seim, H.B., 1984. Spinal fixation in dogs using Steinmann pins and methylmethacrylate. Vet. Surg. 13: 203-210.
- Chrisman C.L. (1982). Problems in Small Animal Neurology Lea & Febiger, Philadelphia. Dulisch, M.L. and Nichols, J.B., 1981. A surgical technique for management of lower lumbar fractures: Case reports. Vet. Surg. 10: 90.
- Gage, E.D. and Hoerlein, B.F. (1968). Hemilaminectomy and dorsal laminectomy for relieving compression of spinal cord in the dog. J.A.V.M.A., 152:351-359.

- Hoerlein, F.F. (1953). Intervertebral Disc Protrusions in the dogs. Incidence and Pathological lesions (ii) Symptomatology and clinical diagnosis. *Am.J.Vet.Res.* 14:260-283.
- Kramer et al. (2001) reported the use of lubricating plates and external skeletal fixators for treatment of fractures and luxations of the thoracolumbar region.
- Lieb, A.S., Grooters, A.M. and Tyler, J.W., 1997. Tetraparesis due to vertebral physal fracture in an adult dog with congenital hypothyroidism. *J. Small Anim. Pract.* 38: 364-367.
- Rouse, G.P. and Miller, J.I., 1975. The use of methyl methacrylate for spinal stabilization. *J. Am. Anim. Hosp. Assoc.* 11: 418-425.
- Shores, A., Braund, K.G. and Brawner, W.R., 1990. Management of acute spinal cord trauma. *Vet. Med.* 85: 724-739.
- Seim, H.B., 1996. Conditions of the Thoracolumbar spine. *Semin. Vet. Med. Surg. (Small Anim).* 11: 235-253.
- Summers, B., Cummings, J. and de Lahunta, A., 1995. *Veterinary Neuropathology*. St. Louis: Mosby, pp. 189-207.
- Tarlov I. M. (1954). Spinal Cord Compression study III time limits for I.M. to recovery after Gradual Compression in dogs. *A.M.A. Arch. Neurol. and Psychial.* 71 :588-597.
- Tarlov, I.M. & Klinger, H. (1954). Spinal Cord Compression studies II, Time Limits for recovery After acute compression in Dogs, *A.M.A. Arch. Neurol. & Psychial.* 271-290.
- Tomsa, K., Glaus, T. and Hauser, 1999. Nutritional secondary Hyperparathyroidism in six cats. *J.Small Anim. Pract.* 40:533-539
- Voss, K. and Montavon, P.M., 2004. Tension Band stabilization of fractures and luxations of the thoracolumbar vertebrae in dogs and cats: 38 cases (1993-2002). *J. Am. Vet. Med. Assoc.* 225: 78-83.
- Walter, M.C., Smith, G.K., McCain, W. and Newton, C.D., 1986. Canine lumbar Spinal internal fixation techniques. A comparative biomechanical study. *Vet. Surg.* 15: 191-198.
- Whaldron, D.R., Shires, P.K., McCain, W., Hedlund, C. and Blass, C.E., 1991. The rotational stabilizing effect of spinal fixation techniques in an unstable vertebral model. *Progress in Vet. Neurol.* 2: 105-110.
- Wheeler, S.J. and Sharp, N.J.H., 1994. Trauma. In *Small animal spinal disorders diagnosis and surgery*. Mosby-Wolfe Publishing Company, London. pp. 171-191.
- Withrow, S.J. (1974). *Localization and Diagnosis of spinal cord lesions in small animals*. Lecture notes, Colorado State University Colorado.

\*\*\*\*\*###\*\*\*\*\*