DILATED CARDIOMYOPATHY IN GERIATRIC DOGS

Dimple Puri, Shahnawaz A. Bhat, Adarsh Thakur and N. A. Sudhan
Department of Veterinary Medicine,
Khalsa College of Veterinary and Animal Sciences, Amritsar – 143001.
[Received: 15.6.2015; Accepted: 03.12.2015]

Dilated cardiomyopathy is an acquired disease reported mostly in aged dogs. It is mainly characterized by poor myocardial contractile function and cardiac chambers enlargement (Nelson, 2009). It most commonly affects large breed dogs, male being more susceptible. Often secondary dilated cardiomyopathy occurs due to L- carnitine deficiency or due to parvovirus infection in dogs (Merck 2010).

Case Study

Five male geriatric dogs of age 9-12 years of different breed, Labrador n=3 and nondescript n=2 were presented with clinical history of reduced appetite, cough and exercise intolerance. Honking cough was observed in one of the five dogs. Dyspnea was observed in 2 dogs however syncope was found in one dog. Ascitis was seen in 3 dogs however limb edema was observed in one of the dog. Among the 5 dogs one dog was associated with vomiting, black stools, polydipsia and polyuria and other dog was associated with seborrhoic dermatitis.

On clinical examination 2 dogs were found to be apparently active and other 3 dogs were found to be in dull and depressed state. Heart auscultation revealed tachyarrythemia in 3 dogs. Weak pulse rate was found to be in 2 dogs. One of the 5 dogs was observed with muffled heart sound due to pleural effusions. Blood analysis revealed normocytic regenerative anaemia in 2 dogs (8-9gm/dl). Serum analysis revealed increase BUN (268 mg/dl) and creatinine (3.1 mg/dl) in the dog with systemic signs of renal azotemia. Hypercholesterolemia was found in 3 dogs (310-477 mg/dl) however hypoprotinaemia was observed in all the dogs (1.2-1.4g/dl). Lateral and ventro-dorsal view of the heart revealed globoid heart and pleural effusions in the chest cavity. Electrocardiographic changes revealed widened P-R interval and QRS complexes, slurring of S-T segment was seen in ECG of 2 dogs. Shortening of the QRS complex was seen in dog with pleural effusion.

Treatment

Therapy is always aimed at controlling signs of heart failure, managing arrhythmia, recovering cardiac output and improving the animals quality of life.

The protocol used for the 5 dogs was digoxin @ 0.25mg/kg p.o, Furosemide @ 2mg/kg and Enalpril@ 0.5mg/kg P.O. and after a period of 2 weeks the animals suffering from ascites revealed complete recovery. Theophylline was given in the dog with pleural effusions @ 10mg/kg p.o. l- carnitine was also supplanted in the form of commercial diets available in the market @ 50 mg/bid.

ECG revealing short QRS complexes in a dog with pleural effusions

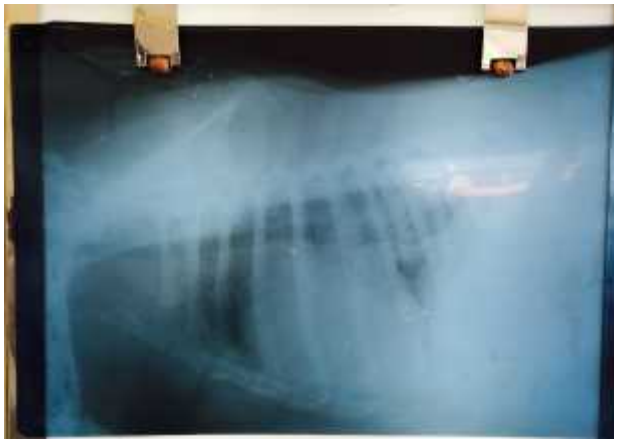

Lateral x-ray of a dog revealing globoid heart and pleural effusions in the chest cavity

Discussion

Dilated cardiomyopathy is characterized by poor myocardial contractality with or without arrhythmias. It mainly occurs with increase in age and affects larger breeds of dogs as also reported by Nelson (2009). Clinical signs include weakness, lethargy, tachypnea or dyspnea, exercise intolerance, cough, anorexia, abdominal distension and syncope as also mentioned by Birchard and Sherding (1999). Treatment therapy includes an angiotensin converting enzyme inhibitor, a diuretic and a strong inotropic agent also, as suggestedby Merck (2010).

References

Nelson, R.W. (2009). Cardiovascular system disorders. In: Nelson R W and Couto C G. *Small Animal Internal Medicine*, 4th edition. Mosby, St.Louis, Missouri. Pp. 106-118.

Merck Veterinary Manual (2010). Cardiova -scular system. In The veterinary merck manual,10thedition. Merck and Co, Inc, White House Station, N.J, U.S.A. Pp. 492-534.

Birchard, J.S. and Sherding, G.R. (1999). Cardiopulmonary system. Saunders manual of small animal practice, 2nd edition. Pp. 443-583.