

ULTRASONOGRAPHIC DETERMINATION OF GESTATION AGE: A REVIEW OF 152 FEMALE DOGS

Apra Shahi¹, Pankaj Jain² and V.P. Chandrapuria³

¹Associate Professor, ²Ph.D. Scholar, ⁴Professor and Head; Department of Veterinary Surgery and Radiology, College of Veterinary Science and Animal Husbandry, Nanaji Deshmukh Veterinary Science University, Jabalpur - 482001(M.P.).

[Received: 01.6.2015; Accepted: 01.12.2015]

Ultrasonographic evaluation of fetal age was performed in 152 female dogs and various fetal structures were identified. Different fetal measurements involving CRL, BD, GSD and HD were taken at different stages of gestation based on which fetal age was determined using certain formulas. No abnormality related to fetal structures was reported during study. It was concluded that GSD before day 40 of pregnancy and HD from day 40 onwards were found to be the most accurate measurements. These measurements could be used to calculate expected delivery date and should be correlated with LH surge and actual delivery date. Appearance of cardiac activity and organogenesis increased the precision of diagnostic procedure however it was not found a good tool to detect the number of fetus accurately.

Key words: Fetus, gestation age, ultrasound.

Early diagnosis of pregnancy has become a common request of dog breeders and they are often anxious to confirm the pregnancy, to determine the number of fetuses, to avoid unwanted or accidental mating. Determination of gestation age is critically important for pregnancy management from 20 days after conception to delivery and is particularly necessary for determining viability in premature labour and in post-dates deliveries (Kalish and Chervenak, 2005). Through radiography detection of fetus does not occur until the mineralization of fetal structures takes place i.e. 45 days, also the radiographic exposure is hazardous for live fetus. However, with ultrasound it is possible to diagnose the pregnancy as early as 25 days post mating. Measurements of various parameters related to fetus *in utero* allows a

sinologist to access the approximate gestation age.

Materials and Methods

Total 152 female dogs thought to be pregnant were presented to Teaching Veterinary Clinical Complex, Jabalpur during the period of 2011-2013. Most of them were non descript 51.3% (78) while Pomeranian 21.1% (32), German Shepherd 17.1% (26), and Labrador 10.5% (16) were also reported in fair number. The body weight of these animals was between 15-27 Kg. All the animals were scanned by using grey scale ultrasound machine in B-mode to confirm the pregnancy. Different fetal measurements such as crown rump length (CRL), body diameter (BD) or body parietal diameter (BPD), gestation sac diameter (GSD) and head diameter (HD) were taken at different stages of gestation. Fetal age was calculated by the formula given by Nyland and Mattoon (Table 1).

Table 1. Gestation age in dog (± 3 days)

For pregnancy less than 40 days	For pregnancy more than 40 days
I. $(6 \times \text{GSD}) + 20$	I. $(15 \times \text{HD}) + 20$
II. $(3 \times \text{CRL}) + 27$	II. $(7 \times \text{BD}) + 29$
	III. $(6 \times \text{HD}) + (3 \times \text{BD}) + 30$

Results and Discussion

Ultrasonographic features during various length of gestation period (i) 20 to 30 days

In early stages on day 20th, to visualize gestation sacs animals were prepared by giving tab Gasex³ to reduce the gaseous content of gastrointestinal tract. Small gestation sac could be recognized

with 8 -10 MHz transducer, whereas with 3 MHz transducer no difference was observed between cross section of intestine and gestation sacs (Fig. 1). Nyland and Mattoon (2002) reported that it was better to wait upto day 30 for determination of fetal age based on GSD as at this stage viable embryo could be identified with high level of confidence. Grisolia *et al.* (1993) stated that two orthogonal inner to inner diameter of gestation sac (horizontal and vertical) should be measured and averaged to get correct GSD. And that is why we followed both of these reports in our study. In this stage, fetal pole appeared as hyperechoic mass present in the anechoic fluid. Intestinal loops could be differentiated by movements of ingesta which were observed by 8 MHz transducer. Fetal cardiac activity was not observed in this stage.

From 25 days onwards fetal cardiac activity was well recognized, although the chambers of the heart could not be visualized. The numbers of gestation sacs were counted at this stage to get an

approximate idea of number of fetuses and fetal age was calculated by measuring GSD using above formula.

(ii) 30-40 days

From day 30 onwards all the organs of fetus were visualized it is in accordance to Aissi and Slimani (2008) who have also detected stomach at 32-35 days and urinary bladder at 33-37 days. At this stage fetal age was calculated by measuring GSD, BD, CRL and HD (Fig. 2, 3, 4 and 5). Out of these, BPD, GSD and HD were found to be the most accurate measurements because most of the time fetuses were curved and CRL could not be measured accurately, which may give wrong gestation age (Fig. 6). Cardiac activity was very prominent at this time, although four chambers could not be well differentiated (Fig.7). Limb buds were recognized as small hyperechoic protrusions in anechoic amniotic fluid (Fig. 8). Rib cage and vertebral column were recognized as hyperechoic structures at this stage. These findings are in accordance with the findings of Sauerbrei *et al.* (1980).

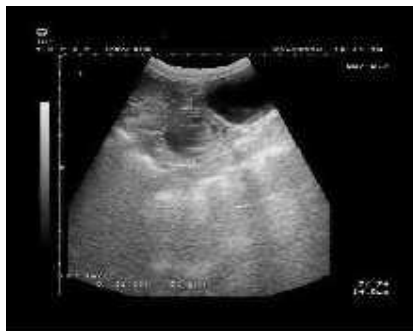

Fig. 1: Gestation sac diameter (20-30 days)

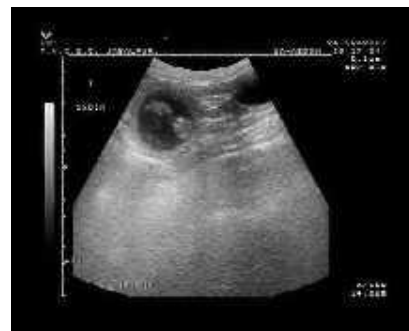

Fig. 2: Gestation sac diameter (30-40 days)

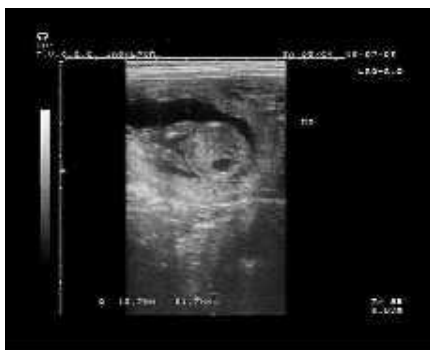

Fig. 3: Body diameter (30 to 40 days)

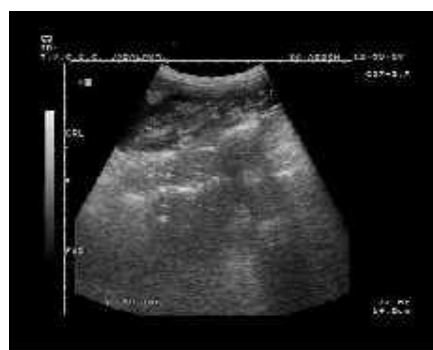

Fig. 4: Crown rump length (30-40 days)

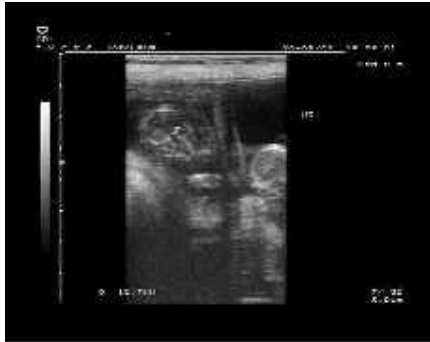


Fig. 5: Head diameter (30-40 days)

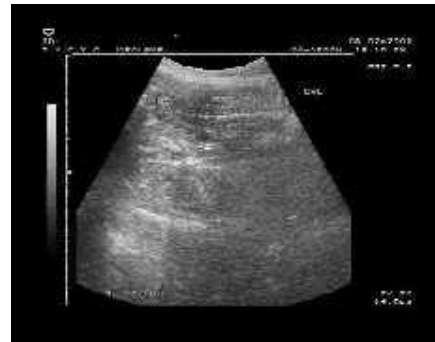


Fig. 6: Curved fetus (30-40 days)

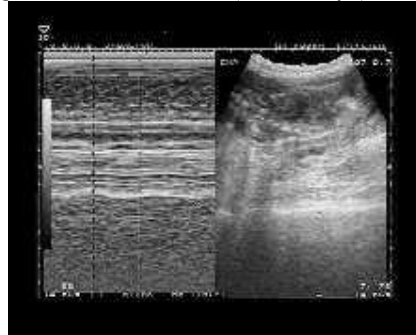


Fig. 7: Cardiac activity in B and M- mode echocardiography (30- 40 days)

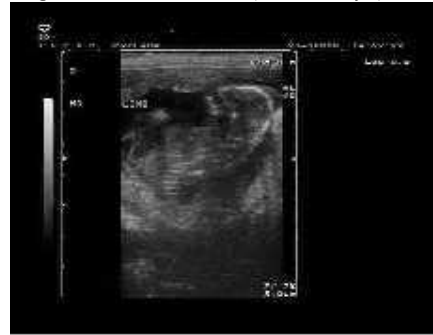

Fig. 8: Limb buds in amniotic fluid (30- 40 days)

(iii) 40-50 Days

From day 40 to 50, the most accurate judgment of fetal age was done by measuring HD and BPD. However, HD was the accurate predictor of gestation age at this stage as also reported by Sridevi (2013). BD was always taken from the cross section of body at the level of anechoic stomach (Fig. 9). From day 40-50 onwards, organogenesis was visible (Fig. 10) which have been also documented by Bharadwaj (2007). Fetal heart appeared as anechoic chamber surrounded by hyperechoic myocardium. Lungs appeared as hypoechoic structures within the rib cage (Fig.11). Ribs and vertebrae gave

hyperechoic image with distal acoustic shadow because of mineralization. Neural canal was visualized to diagnose neurological disorders. It appeared as an even anechoic tubular canal running from neck to pelvis (Fig. 12). However, no neurological disorder was observed during this period. Head could be imaged in sagittal and transverse plane. Both the hemispheres appeared hypoechoic. Eye sockets appeared as anechoic holes, while jaw and teeth appeared as hyperechoic structures (Fig. 13). Jaw movements were detected in this stage. These findings are in accordance with the results of Bharadwaj (2007).

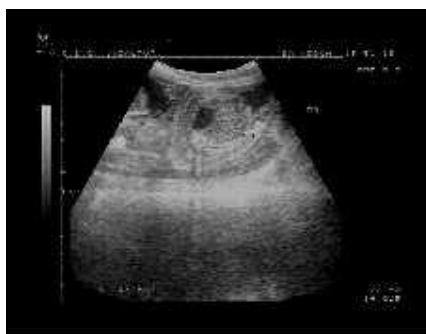

Fig. 9: Body diameter at the level of anechoic

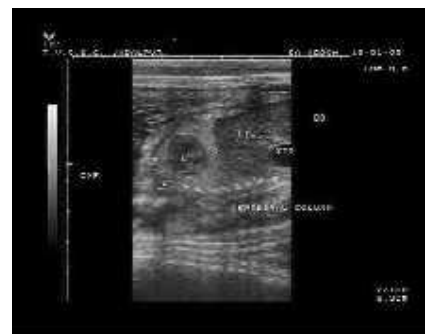


Fig. 10: Organogenesis showing lungs, heart,

stomach (40-50 days)

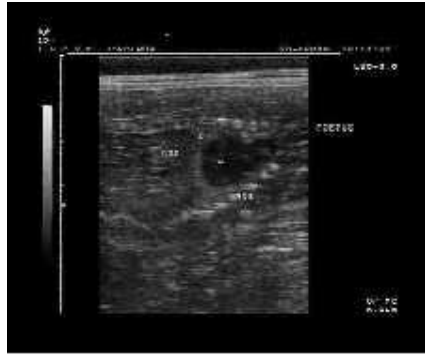


Fig. 11: Lungs and heart in rib cage (40-50 days)

diaphragm, liver and stomach (40-50days)

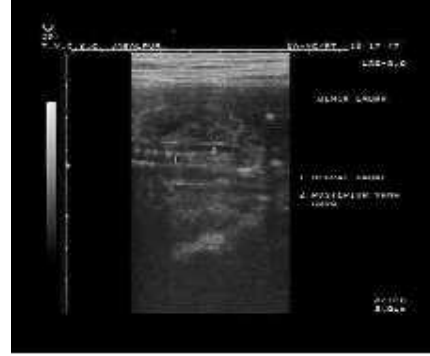


Fig. 12: Neural canal and posterior vana cava (40-50 days)

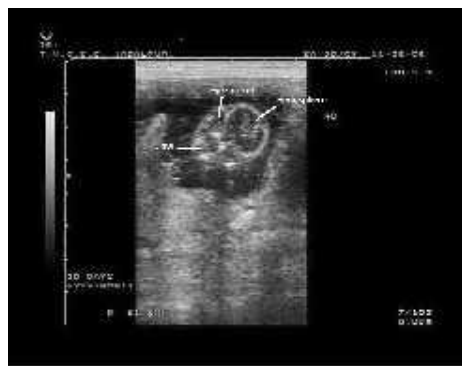


Fig. 13: Head showing both hemispheres, Eye sockets and jaw

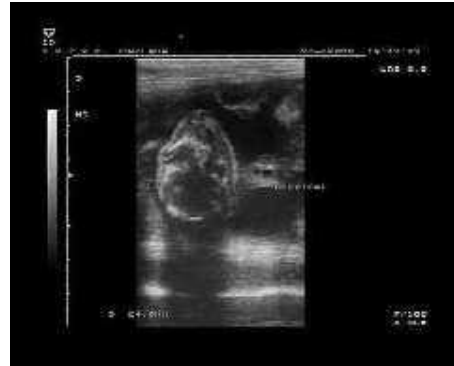


Fig. 14: Head diameter (50-60 days)

(iv) 50-60 days

All the organs could be recognized clearly at this stage. Fetal age was calculated by measuring BPD and HD. However, BPD could not be measured accurately and most of the time difference of $\pm 3-4$ days was observed. At this stage HD provided accurate results (Fig. 14).

Lungs, heart, kidneys, urinary bladder, diaphragm, humerus and femur can be diagnosed and measured. At this stage number of fetuses could not be detected because they overlapped each other and in one field, only one fetus could be detected. Amniotic fluid and placenta were well visualized. Based on these findings of ultrasound and gestation age calculated using the formulae, animals were divided into four groups (Table 2).

Table 2. Distribution of animals in to different groups based on gestation age

Group	No of animals	Range of gestation age
I	35	20-30 days
II	39	30-40 days
III	36	40- 50 days
IV	42	50-60 days

CRL, GSD, HD and BD were calculated by using the different formulae

at different length of gestation and Mean \pm SE were derived (Table 3).

Table 3. (Mean ± SE) values of GSD, CRL, HD and BD in different groups

Group	GSD (cm)	CRL (cm)	HD (cm)	BD (cm)
I	1.3 ± 0.38 (0.9 - 1.6)	1.1 ± 0.86 (0.9 - 1.4)	-----	-----
II	2.7 ± 0.75 (1.9 - 2.9)	2.7 ± 0.64 (2.2 - 2.8)	-----	-----
III	----	-----	1.7 ± 0.28 (1.3 - 2.1)	2.4 ± 0.31 (2.1 - 2.6)
IV	-----	-----	2.6 ± 0.46 (2.2 - 2.8)	4.3 ± 0.32 (4.1 - 5.2)

BD and HD could not be measured up to 40 days of gestation as ossification has not commenced at this stage. Similarly, from day 45 onwards it was difficult to measure the CRL because of bending of fetus which made it impossible to take accurate measurements for CRL. Gestation age obtained using these formulae did not differ significantly.

Conclusion

In this study CRL, GSD, BD and HD were used for the estimation of gestation age by ultrasonographic evaluation. Of these, GSD before day 40 of pregnancy and HD from day 40 onwards were found to be the most accurate measurements. These should be correlated with appearance of cardiac activity and organogenesis to increase the precision of diagnostic procedure.

References

- Aissi, A. and Slimani, C. (2008). Ultrasonographic appearance of the gestational structures throughout pregnancy in bitches. *Am. J. Anim. Vet. Sc.*, **3**(1): 32-35.
- Bharadwaj, J. (2007). Studies on pregnancy diagnosis and fetal age development in German Shepherd bitches by ultrasound. M.V.Sc. thesis, submitted to J.N.K.V.V., Jabalpur, M.P.
- Grisolia, G., Milano, K., Pilu, G., Banzi, C., David, C. and Gabrielli, S. (1993). Biometry of early pregnancy with transvaginal sonography. *Ultrasound Obstet. Gynecol.*, **3**: 403-411.
- Kalish, R.B. and Chervenak, F.A. (2005). Sonographic determination of gestational age. *Ultrasound Obstet. Gynecol.*, **5**: 254-258.
- Nyland, T.G and Mattoon, J.S. (2002). *Small Animal Diagnostic Ultrasound*. 2nd Edn., Saunders Publishing Co., USA. Pp. 461.
- Sauerbrei, E., Cooperbeg, P.L. and Poland, J.B. (1980). Ultrasound demonstration of the normal fetal yolk sac. *J. Clin. Ultrasound*, **8**: 217-220.
- Sridevi, P. (2013). Ultrasonographic diagnosis and monitoring of pregnancy in the bitch - a review. *J. Vet. Anim. Sc.*, **44**: 1-7.