AORTIC BODY TUMOR IN A DOG

Mukesh Kumar Srivastava[1], Shanker Kumar Singh, Alok Kumar Chaudhary, Vivek Malik[2], Kapil Gupta, Alok Singh and Hemant Shah

[1]Assistant Professor & I/c, Department of Veterinary Medicine; [2]Assistant Professor, Department of Surgery; College of Veterinary Science & A.H, DUVASU, Mathura (U.P.) India.

[Received: 21.3.2016; Accepted: 14.10.2016]

Present case report describes aortic body tumor in a 8 year old male Pomeranian dog. Presenting complaints were severe dyspnoea, open mouth breathing, reduced activity and appetite since last two weeks. Clinical examination revealed cyanotic mucous membrane, crackle and wheeze on auscultation. Electrocardiography showed cor--pulmonale and notch in the QRS complex. Radiography showed trachea parallel to the spine, VHS score of 12.5, pulmonary edema and two high density masses at the base of heart, which pushes the trachea. Diagnosis was made for aortic body tumor and dog was tried to be stabilize, but within six hours of diagnosis dog succumb.

Key words: Aortic body tumor, Cor-pulmonale, Dog, Radiography

Chemodectoma represents both aortic body tumors and carotid body tumors (Ehrhart *et al.,* 2002). Aortic body tumors are four to five times more common than carotid body tumors in dogs (Deim *et al.,* 2007). Synonyms include cardiac paraganglioma, heart base tumor and glomus body tumor. An aortic body tumor located at the base of the heart and arises from the chemoreceptor organs that are localized in the tunica adventitia of the aortic arch, encountered frequently in dogs, but are rarely seen in cattle and cats. Although primary cardiac tumors are rare, but aortic body tumor is the second most common cardiac tumor, after haemangiosarcoma, and represents 7% of all primary cardiac tumors in dogs. Aortic body tumors have been frequently found in brachiocephalic breeds such as the Bulldog, Boston terrier and boxer as they are genetically predisposed (Gliatto *et al.,* 1987). Aortic body tumors are non-functional but can cause functional disturbances when they increase in size and exert pressure on surrounding organs i.e. the trachea or cardiac atria (Withrow and Veil, 2007), additionally functional disturbances such as compression of the aorta and vena cava which causes cardiac decompensation. The tumors are of clinical relevance because they can cause hemorrhages and cardiac failure. Aortic body tumors seldom metastases; instead they have a tendency of being infiltrative, however when they metastasize, lungs, liver, brain, the mediastinum, the bones, the kidney, the adrenal cortex, the spleen, mediastinal lymph nodes, the duramater in the cerebellum and myocardium may be affected (Noszczyk-Nowak *et al.,* 2010). Regarding etiology, one theory suggests that chronic hypoxia causes chemoreceptor cell hyperplasia (Withrow and Veil, 2007) which can result in neoplasia of the chemoreceptor cells (Noszczyk-Nowak *et al.,* 2010). The incidence of aortic body tumors is higher in dogs aged 6 years or older but the incidence is lower in dogs aged 15 or older (Atasever and Çam, 2003). Present case report describes aortic body tumor in a 8 year old male Pomeranian dog.

Case Histroy and Observation

An eight year old male Pomrarian dog of about 14 kg presented at TVCC, Veterinary College, DUVASU, Mathura with the complaint of severe dyspnoea, open mouth breathing, reduced activity and appetite since last two weeks, the dog was unresponsive for previous antibiotic, bronchodilator and antihistaminic therapy. Clinical examination revealed cyanotic mucous membrane, crackle and wheeze on auscultation. Pulse was weak in strength along with tachycardia (135 beats/ min). Parotid, mandibular, and the retropharyngeal lymph nodes were normal. Heamatology showed leukocytosis, neutrophilia and mild anemia. Radiography showed trachea parallel to the spine, VHS score of 12.5, pulmonary edema and two high density masses at the base of heart, which pushes the trachea. (Fig.1). Electrocardiography (25mm/sec and 10mm/mV) showed heart rate of 140/min, P wave of varying amplitude with an average of 4.0-4.5 mV. Tall P waves are referred to as P-

pulmonale (right atrial enlargement may be associated with cor pulmonale), which may be seen in chronic airway disease. Rthym was of sinus origin, but there was notch in the QRS complex, which was indicative for microscopic intramural myocardial infarction or myocardial fibrosis (Fig.2). Based on the clinical examination, finding of radiography case was diagnosed for aortic body tumor.

Treatment and Discussion

With the aim of stabilization, treatment was started with nebulization with Budesonide @ 0.5 mg and levosarbutamol 1.25 mg with ipratropium bromide 500µg separately and alternatively. Medical therapy was extended with antibiotic Cefpodoxime oral suspension @ 5-10 mg per kg body weight SID, furosemide @ 2mg/kg through i/v route. The dog remains stabilized for 5-6 hrs, after which started to show sign of severe dyspnoea and open mouth breathing, this time nebilization with same drugs was done. But unfortunately no clinical improvement seen this time and final dog succumb with the sign of cyanosis.

Signs of dyspnoea, fatigue, edema, decreased activity, cough observed in this case were similar to previous case reports by Withrow and Veil (2007). Pressure on the main bronchus cause by tumor along with pulmonary edema is the suggested cause of dyspnea as also reported by Noszczyk-Nowak *et al.* (2010). Radiographic sign in this tumor are peri-hilar mass, pleural effusion, pulmonary edema as also mentioned by Ehrhart *et al.* (2003) along with dorsal elevation of the trachea near the heart base. Leukocytosis with neutrophilia is might be due to secondary bacterial infection of lungs as also narrated by Cho *et al.* (1998), the hematological values are generally within the normal range as seen in this case as also reported by Capen (1990). Tumors may appear as a single mass or multiple nodules with a mosaic pattern with smooth external surface as also mentioned by Arlington-Headley *et al.* (2009).

Fig.1 Radiograph showing cardiomegaly, two masses at the base of heart in the dog with aortic tumor

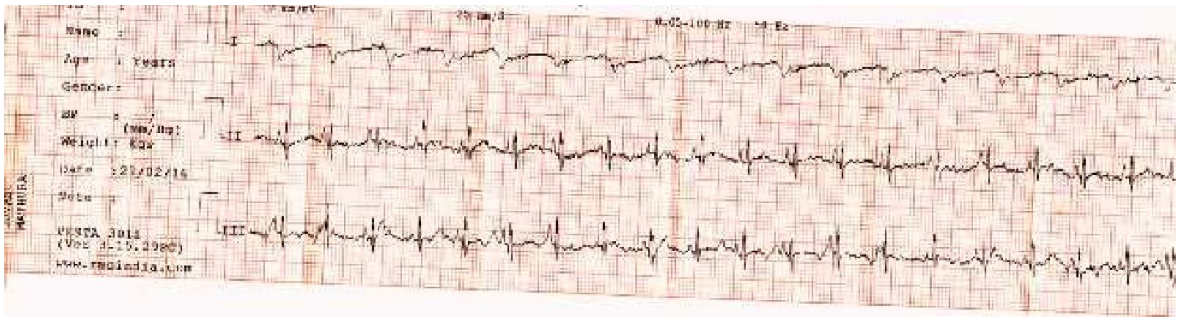

Fig.2 ECG showing Cor- pulmonale and notch in R wave in a dog with aortic tumor

Conclusion

Medical management of dogs remains unsuccessful many times that are diagnosed

with aortic body tumors, however they may get benefit from a pericardectomy at the time of surgical biopsy.

References

Arlington-Headley, S., Bracarense, A.P., Nakagawa, T., Moreno, K., Mendes Pereira, P. and Faria dos Reis, A.C. (2009) Aortic body tumors in dogs from Northern Paraná, Brazil. Ciência Rural, **6**: 1908-1912.

Atasever, A. and Çam, Y. (2003) Aortic body tumor in a dog. Turkish Journal of Veterinary Animal Science, **27**: 1241-1245.

Capen, C.C. (1990) Tumors of the Endocrine Glands. In Tumors of Domestic Animals. 3rd Edn., (Moulton, J.E. ed.), University of California Press, Berkeley, U.S.A. Pp.553-639.

Cho, K.O., Park, N.Y., Park, I.C., Kang, B.K., Onuma, M. (1998) Metastatic intracavitary cardiac aortic body tumor in a dog. J. Vet. Med. Sci., **60**: 1251-1253.

Deim, Z., Szalay, F., Glávits, R., Bauer, A. and Cserni, G. (2007) Carotid body tumor in dog: A case report. Can. Vet. J., **48(8)**: 865–867.

Ehrhart, N., Ehrhart, E.J., Willis, J., Sisson, D., Constable, P., Greenfield, C., Manfra-Maretta, S. and Hintermeister, J. (2002) Analysis of factors affecting survival in dogs with aortic body tumors. Veterinary Surgery, **31**:44-48.

Gliatto, J.M., Crawford, M.A., Snider-III, T.G., Pechman, R. (1987) Multiple organ metastasis of an aortic body tumor in a boxer. J.Am. Vet. Med. Assoc., **191**: 1110-1112.

Noszczyk-Nowak, A., Nowak, M., Paslawska, U., Atamaniuk, W. and Nicpon, J. (2010) Cases with manifestation of chemodectoma diagnosed in dogs in Department of Internal Diseases with Horses, Dogs and Cats Clinic, Veterinary Medicine Faculty, University of Environmental and Life Sciences, Wroclaw, Poland. Acta Veterinaria Scandinavica, 52.

Withrow, S. J. and Vail, D. M. (2007) Small animal clinical oncology. 4th Edn., Saunders Elsevier, Missouri, U.S.A. Pp.809-812.