CHONDROSARCOMA IN A DOG

M.S.Vasanth
Dean, Veterinary College, KUVAFS, Gokula, Vidyanagar Post, HASSAN- 573 202 (Karnataka).
[Received: 05.6.2016; Accepted: 06, 12. 2016]

Chondrosarcoma (CSA) of the bone is a fast spreading and malignant form of cancer, which, if not diagnosed and treated early, can be life threatening. Chondrosarcoma arises from the cartilage of the body, the connective tissue that is found between the bones and joints, often metastasizing to other parts of the body, including the ribs. This is the most common rib tumor found in dogs, and the second most common primary tumor in dogs, representing 5 to 10 percent of all primary bone tumors. Fourie *et al.* (2011) reported soft tissue sarcomas are a group of malignant cancers that arise from the skin and subcutaneous connective tissues, such as fat (liposarcoma), muscle (rhabdomyosarcoma, leiomyosarcom -a), cartilage (chondrosarcoma). Neoplastic conditions occur frequently in dogs, however malignant neoplasm of the cartilaginous tissue is of rare occurrence especially that of appendicular skeleton (Brodey *et al.,* 1974). Chondrosarcomas account for about 10% of all bone sarcomas (Brodey *et al.,* 1963; Brodey *et al.,* 1974; Ling *et al.,* 1974). Large breed dogs are affected most frequently (Brodey *et al.,* 1974; Ling *et al.,* 1974). In a study by Brodey *et al.* (1974), Boxers were accounted for 25% of all cases of chondrosarcoma and a high incidence was also found for German shepherds and mixed-breed dogs. In the dog, flat bones of the body are more commonly affected by chondrosarcoma (Brodey *et al.,* 1974; Ling *et al.,* 1974). Brodey *et al.,* (1974) reported that the major sites of origin were the ribs (29%), nasal Cavity (26%), and pelvis (14%).

Chondrosarcoma is a malignant tumor in which the cells produce a neoplastic chondroid and fibrillar matrix but never directly produce neoplastic osteoid or bone. The cartilaginous neoplasms do not directly produce bone or osteoid tumours (GoldSchmidt and Throll, 1985). Chondrosarcomas may be primary, arising within a bone (central) or from the periosteum (peripheral), or secondary, arising by malignant change in osteochondromas (Spjut *et al.,* 1971). Primary chondrosarcoma and osteochondrosarcoma are malignant, slow-growing and locally invasive tumors of skeletal and extraskeletal cartilage (Cohen *et al.,* 2010) and are the second most common primary bone tumor in both humans and dogs; and it accounts for approximately 5% to 10% of all canine primary bone tumors (Straw, 1996). Chondrosarcomas may be primary, arising within a bone (central) or from the periosteum (peripheral), or secondary, arising by malignant change in osteochondromas (Spjut *et al.,* 1971). They can be found in large-breed dogs of any age (Popvitch *et al.,* 1994), affecting the ribs (Halfacree *et al.,* 2007), in the appendicular skeleton, mammary gland, penile urethra (Davis and Holt, 2003), digit, tongue, kidney, liver (Chkata *et al.,* 2006), abdominal wall, scapula (Norton *et al.,* 2006), skull (Kim *et al.,* 2007), nasal cavity, pelvis (Ling *et al.,* 1974), eye (Rodrigues *et al.,* 2009), heart (Dupuy-Mateos *et al.,* 2008), aorta (Lee *et al.,* 2011), spleen (Miller *et al.,* 2005) and lungs (Brodey *et al.,* 1974). A rare case of chondrosarcoma of femur in a dog is reported in the present study.

Case history and observations

A male, Doberman dog aged 4 years was presented to the hospital with the history of a huge swelling on the left thigh of the dog persisting since about 2 months subsequent to a fracture for which no treatment was given. On examination, left thigh region was grossly enlarged and there was edema of the distal part of the limb. Palpation of the limb revealed a hard and solid painless swelling. The animal was not bearing weight on affected limb and was dragging the limb leading to abraded wound on dorsal aspect of the left foot.

Lateral and AP radiographic view of the left hind limb showed a transverse fracture of the femur. A dense radio opaque mass was seen attached to the proximal fracture segment.

A routine haematology revealed all the values within the normal range. Tissue samples from the local lymph nodes were also taken for analysis of cancer cells and evidence of immune system response. A punch biopsy was made and histopathological examination of the sample revealed proliferating plemorphic chondrocytes with increased mitotic activity and without any central area of necrosis, suggestive of a low grade chondrosarcoma. Hence it was decided to ampute the affected limb.

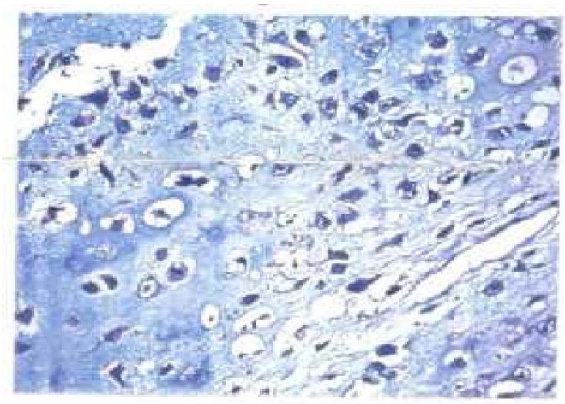

Fig.1: Photomicrograph showing proliferatingplemorphic chondrocytes

Treatment and Discussion

The dog was sedated with Triflupromazone hcl (Siquil, Zydus Chemicals) @ 1mg/ 1kg, given intravenously and the left hind limb was prepared for aseptic surgery. General anaesthesia was induced and maintained using Thiopentone Sodium at the dose of 12.5 mg/kg given to the effect. Surgical site was painted with povidone iodine. An elliptical incision was made just below the hip joint and the limb was amputed as per the standard procedure ensuring complete excision of tumorous mass. All bleeding points were arrested by ligation with chromic catgut no.0. Subcutaneous suturing was done with chromic catgut no.0 in simple continuous manner and skin was apposed with linex no.0 in horizontal mattress.

Ciprofloxacin, (Ciflox, Intas Pharmaceuticals) 10 mg/kg s/c was given as post operative antibiotic daily for 7 days along with routine wound dressing. Skin sutures were removed on 10th post-operative day. The dog recovered uneventfully and there was no recurrence of the lesion with observation period of one year after the surgery; as routine X-rays were taken of the affected part and other body areas to check for recurrence and spread of the tumor.

Chondrosarcoma is a malignant cartilage producing neoplasm that usually arises within the bone or occurs at the site of any previous bone lesion. It may be primary arising from the bone or from the periosteum or secondary through metastasis from other tissues (Waters, 1993). Chondrosarcoma is a relatively uncommon bone neoplasm in dogs and is found in the ribs, nasal cavity and the flat bones. It is comparatively rare in long bones like femur (Utpal Das, 1997). Clinically affected dogs usually present with multiple soft-tissue masses in the affected area with regional swelling. When involving the limbs, lameness is a consistent finding. Diagnosis is based on clinical presentation, often associated with swelling in the surrounding tissue. Radiography may display osteolyis of neighbouring bone and osteolytic regions associated with the tumor. Chondrosarcoma of long bones tend to produce large tumor mass with a dense radio opaque shadow thereby making differential diagnosis of chondrosarcoma very difficult. A definitive diagnosis in such cases can be achieved only through bone biopsy (Morgan,

1972). A definitive diagnosis requires histopathology, with characteristic chondrocytes with marked nuclear pleomorphism and a high mitotic rate. Histologically, two different types of chondrosarcoma are recognized: myxoid, the most common type found in skeletal tumors, and mesenchymal, a rarer type found more often in extraskeletal sites (Kojima *et al.,* 2012).

Appendicular chondrosarcoma is one of the few canine primary bone neoplasm's with a favourable prognosis for cure after amputation since it is less likely to recur locally and chances of metastasis is also very less (Vasseur, 1985). Appendicular chondrosarcoma can be treated effectively with amputation alone. Low to intermediate grade chondrosarcoma has a good prognosis, whereas high-grade tumors appear to behave aggressively (Farese *et al.,* 2009). Amputation is almost always well tolerated by the patient – dogs with 3 legs can do virtually everything that 4- legged dogs can do. The surgery serves two purposes; it removes the tumor, which is necessary for cancer control, but it also removes the source of pain, and may therefore dramatically improve quality of life. In the present case amputation of the limb was a successive line of treatment to save the life of the pet.

Summary

A rare case of chondrosarcoma is, in the femur of a dog and its successful treatment is reported.

References

Brodey, R.S., Sauer, R.M. and Medway, W. (1963) Canine bone neoplasms. J.Am.Vet. Med. Assoc.; **143**: 471.

Brodey, R.S., Misdorp, W., Riser, W.H. *et al.,* (1974) Canine skeletal chondrosarcoma: A clinicopathologic study of 35 cases. J.Am.vet.Med.Assoc., **165**: 68.

Chikata, S. *et al.,* (2006) Primary Chondrosar -coma in the liver of a dog. Vet Pathol., **43(6)**: 1033-1036 .

Cohen, L. *et al.,* (2010) Non-skeletal multicentric chondrosarcoma in the hindlimb of a dog. J. Small Anim. Pract., **51(10)**: 553-557.

Davis, G.J. and Holt, D. (2003) Two chondro-sarcomas in the urethra of a German Shepherd dog. J. Small Anim. Pract., **44**: 169–171.

Dupuy-Mateos, A. *et al.,* (2008). Primary cardiac chondrosarcoma in a paced dog. Vet. Rec., **163(9)**: 272-273.

Farese, J.P. *et al.,* (2009) Biologic behavior and clinical outcome of 25 dogs with cani -ne appendicular chondrosarcoma treated by amputation: a Veterinary Society of Surgical Oncology retrospective study. Vet. Surg., **38(8)**: 914-919.

Fourie, Y., Heidenreich, D. and Barreau, P. (2011) Canine distal hindlimb soft tissue sarcoma – a novel approach to surgical defect closure. Vet.Comp.Orthop. Traumatol., **1**: 84-88.

Gold Schmidt, B.N. and Throll, M.C. (1985) Malignant bone tumors in dogs: In Newton, C.D and Nummamaker, D.M. (ed): Text book of small animal orthopaedics, JB Lippincott Company, Philadelphia, U.S.A. Pp.891-892.

Halfacree, Z.J. *et al.,* (2007) Use of a latissimus dorsi myocutaneous flap for one-stage reconstruction of the thoracic wall after en bloc resection of primary ribs chondrosarcoma in five dogs. Vet. Surg., **36(6)**: 587-592.

Kim, H. *et al.,* (2007) Primary Chondrosarco-ma in the skull of a dog. J.Vet.Sci., **8(1)**: 99-101.

Kojima, D. *et al.,* (2012) Extraskeletal myxoi-d chondrosarcoma with systemic metastas -is in a five-month-old Irish setter dog. J.Vet.Med.Sci., **74(8)**: 1045-1049.

Lee, B.R. *et al*., (2011) Abdominal aortic chondrosarcoma in a dog. J.Vet.Med.Sci., **73(11)**: 1473-1476.

Ling, G.V., Morgan, J.P. and Pool, R.R. (1974) Primary bone tumors in the dog: A combined clinical, radiographic and histologic approach to early diagnosis. J.Am.vet.Med.Assoc., **165**: 55.

Miller, J.M. *et al.,* (2005) Primary splenic mesenchymal chondrosarcoma in a dog. Can.Vet.J., **46(2)**: 163-165.

Morgan, J.P. (1972) Radiology in veterinary

orthopaedics. Lea & Febigar. Philadelphia, U.S.A. Pp. 139-142.

Norton, C. *et al.,* (2006) Subtotal scapulectom -y as the treatment for scapular tumour in the dog: a report of six cases. Aust.Vet.J., **84(10)**: 364-366.

Popvitch, C.A., Weinstein, M.J., Goldschmidt , M.H. and Shofer, F.S. (1994) Chondrosa -rcoma: a retrospective study of 97 dogs (1987-1990). J.Am.Anim.Hosp.Assoc., **30**: 81–85.

Rodrigues, E.F. *et al.,* (2009) Metastatic intraocular chondrosarcoma in a dog. Vet.Ophthalmol., **12(4)**: 254-258.

Spjut, H.L., Dorfman, H.D., Fechner, R.F. *et al.,* (1971) Tumors of bone and cartilage. In Atlas of Tumor Pathology, 2nd series, fascicle 5. Armed Forces Institute of Pathology, Washington, DC, U.S.A.

Straw, R.C. (1996) Tumors of the skeletal system. In: Withrow SJ, MacEwen EG, editors. Small Animal Clinical Oncology. 2nd Edn., W.B.Saunders Company, Saunders: Philadelphia, U.S.A. Pp.287–315.

Utpal Das, Gupta, R.N. and Dey, S.K. (1997). Chondrosarcoma involving digital extensor mucle muscle in a dobermann dog. Indian J.Vet.Surg., **18(2)**: 102.

Vasseur, P.B. (1985). Limb salvage in a dog wit Chondrosarcoma of the tibia. J.Am.Vet.Med. Assoc., **187**: 620.

Waters, D.J. (1993). In Slatter D. (ed). Text book of small animal surgery. 3rd Edn., W.B.Saunders Company, Saunders: Philadelphia, U.S.A. Pp.2218-2219.