# CONGENITAL MEGAESOPHAGUS IN A PUPPY

**Mukesh Kumar Srivastava[1], Ashish Srivastava, Sanjay Purohit, Arvind Tripathi, Kapil Gupta, Alok Kumar and Hemant Shah**

[1]Assistant Professor & I/c, Department of Veterinary Medicine, College of Veterinary Science & A.H, DUVASU, Mathura (U.P.) India.

[Received: 21.3.2016; Accepted: 14.10.2016]

Congenital megaesophagus was diagnosed and treated in a 45 day old Germen Shepherd pup. Contrast radiography with barium showed enlargement of esophagus and pulmonary exudation. Hematology revealed anemia and neutrophilia with leucocytosis was indicative for secondary complication of aspiration pneumonia. Treatment was done with intravenous fluid therapy, amoxicillin with clavulanic acid, proton pump inhibitors and sucralfate as per standard dosage, route and schedule recommended for dogs. Also, the owner was advised to give small amount of high-caloric diet at frequent intervals in upright position and keep the puppy in vertical position for at least 20 minutes after meal to assist passage of ingesta into the stomach. In spite of treatment, complications were recorded in the form of aspiration pneumonia, esophagitis and puppy died within two weeks of therapy.

**Keywords:** Megaesophagus, Regurgitation, Congenital, Puppy

Megaesophagus is a syndrome of segmental or diffuse dilatation of the esophagus (Johnson *et al.,* 2009) due to several causes including hypomotility and loss of normal peristaltic activity or obstruction and characterized by decreased peristalsis of the esophagus, condition can be classified into congenital and acquired forms (Washabau, 2003). Congenital megaesophagus can be due to a combination of neurologic dysfunction within the afferent arm of the swallowing reflex, altered esophageal viscoelastic properties, and poor vagal responsiveness to intraluminal esophageal distention (Wray and Sparkes, 2006). Congenital idiopathic megaesophagus is known to be inherited condition in many breeds of dogs including German shepherd, Great Dane, Golden retriever, Irish setter and Labrador. Classical signs of this disorder include regurgitation, weight loss, coughing and halitosis; in addition conversion of puppy to solid feed at the time of weaning becomes difficult (Sacha *et al.,* 2012). Combined therapy of prokinetic and vertical feeding gives best recovery from regurgitation, improving esophageal function and body condition (Johnson *et al.,* 2009). However, promotility drugs (cisapride, metoclopramide) have no effect on striated muscle and therefore does not provide any benefit in managing canine megaesophagus. In contrast, they increase lower esophageal sphincter pressure, may hinder esophageal emptying and worsen regurgitation. Prognosis for congenital disorder is always poor due to lack of specific treatment and high complication rate of aspiration pneumonia and mostly the patient succumb within one year.

**Observations and Treatment**

A 45 days old Germen shepherd pup was presented at TVCC, Veterinary College, DUVASU, Mathura with the history of persistent regurgitation either immediate or within 15-20 minutes of feeding, coughing along with inability to thrive well. Clinical examination revealed salivation, sunken eyes and rough skin coat along with mucopurulent nasal discharge. Hematology was unremarkable except mild anemia (5.8 gm %), neutrophilia (98%) and leukocytosis (16000/cu mm). Vital parameters were almost within normal range except mild tachycardia and dyspnoea. Plain radiograph did not reveal any useful information (Fig-1) and puppy underwent contrast radiography with barium which showed enlargement of esophagus and pulmonary exudation (Fig-2 and Fig-3). Based on history, symptoms, clinical examination and radiography case was diagnosed for congenital megaesophagus. Treatment was done by using intravenous fluid therapy, amoxicillin with clavulanic acid, proton pump inhibitors, and sucralfate as per standard dosage, route and schedule recommended for dogs. The owner was advised to give small amount of high-caloric diet at frequent intervals in upright position and keep the puppy in vertical position for

atleast 20 minutes after meal to assist passage of ingesta into the stomach with the help of gravity. In spite of treatment, complications were recorded in the form of aspiration pneumonia and esophagitis and puppy died within two weeks of therapy.

**Fig-1 Plain radiograph of puppy with megaesophagus**

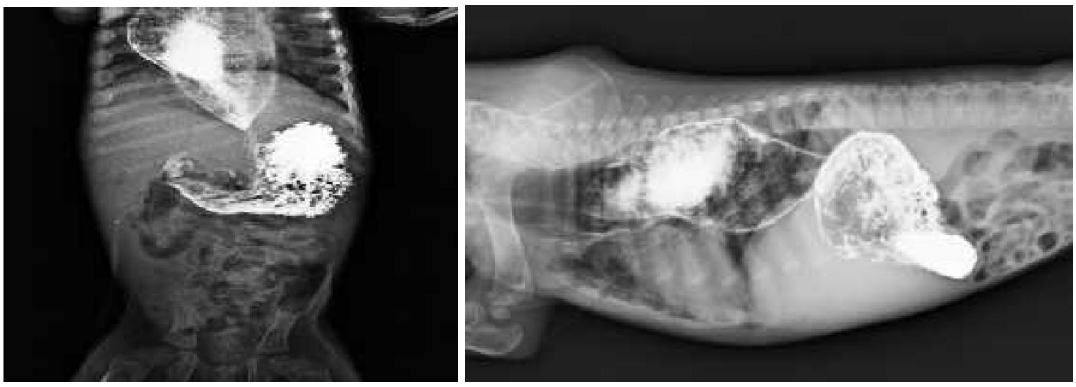

**Fig-2 Barium contrast radiograph after 15 minute (Ventro-dorsal and Lateral)**

**Fig-3 Barium contrast radiograph after 30 minutes (Ventro-dorsal and Lateral)**

**Discussion**

As seen in present case megaesophagus may occur as a congenital disorder that becomes clinically apparent at or shortly after weaning. The suspected etiology for congenital megaesophagus is esophageal hypomotility, which is due to delayed maturation of esophageal function in few cases that may or may not improve with age as also reported by Bexfield *et al.* (2006). Clinical symptoms were similar as described by Sacha *et al.* (2012), the time of regurgitation after feeding was variable. The hematological alteration like anemia and neutrophilia were possibly due to malnutrition and secondary complication. Present case did not responded for the therapy and feeding practice advised to owner, therefore it is concluded that the prognosis varies with the underlying disease and especially the

presence of complications such as aspiration pneumonia or malnutrition. Age of presentation has also been reported to be associated with survival. Morbidity and mortality depends on the degree and nature of the underlying disease and client compliance. A recent study showed that dogs more than 13 months old at the time of onset of clinical signs were 6.4 times as likely to die at a given point of time point compared to dogs less than 13 months old as also mentined by McBrearty *et al.* (2011). Congenital megaesophagus is an inherited autosomal recessive condition in few breeds of dogs due to deficiency of acetylcholine receptors at the neuromuscular junction as also recorded by Shelton (2002).

**References**


Bexfield, N.H., Watson, P.J. and Herrtage, M.E. (2006) Esophageal dysmotility in young dogs. J. Vet. Intern. Med., **20(6)**: 1314-1318.

Johnson, B.M., Denovo, R.C. and Mears, E.A. (2009) Canine Megaesophagus in Kirk's Current Veterinary Therapy (Edited Bonaguru J D and Twedt D C), 14th Edn., Saunder Elsevier, Missouri, U.S.A. Pp.486-492.

McBrearty, A.R., Ramsey, I.K., Courcier, E.A., Mellor, D.J.and Bell, R. (2011) Clinical factors associated with death before discharge and overall survival time in dogs with generalized megaesophagus. J. Am. Vet. Med. Assoc., **238(12)**: 1622-1628.

Sacha, Mace, Diane, Shelton, G. and Susan, Eddlestone (2012) Megaesophagus. Vetlearn. Compendium: Continuing Education for Veterinarians. E-1-8

Shelton, G.D. (2002) Myasthenia gravis and disorders of neuromuscular transmission. Vet. Clin. North. Am. Small Anim. Prac., **32(1)**: 189-206.

Washabau, R.J. (2003) Gastrointestinal motility disorders and gastrointestinal prokinetic therapy. Vet. Clin. North. Am. Small. Anim. Pract., **33(5)**: 1007-1028.

Wray, J.D. and Sparkes, A.H. (2006) Use of radiographic measurements in distinguishing myasthenia gravis from other causes of canine megaesophagus. J. Small Anim. Pract., **47(5)**: 256-263.