SERTOLI CELL TUMOUR WITH SPERMATIC CORD TORSION IN A CRYPTORCHID LABRADOR DOG

B. Bibin Becha[1], K.S. Swetha[1], Debajyoti Sarkar[2] and G. Sudha[3]
[1]Ph.D. Scholars, [2]MVSc Student and [3]Associate Professor, Department of Veterinary Gynaecology & Obstetrics,
Veterinary College, Karnataka Veterinary, Animal and Fisheries Sciences University,
Hebbal, Bengaluru – 560 024.
[Received: 09.6.2016; Accepted: 08.12.2016]

A ten and half year old male Labrador dog was presented with a history of abdominal discomfort, difficulty in urination and dribbling of urine. Animal was having bilateral alopecia and gynecomastia. Physical examination revealed bilateral cryptorchidism and large fluctuating mass in the abdominal cavity. Ultrasonography revealed two large masses of size (5×5 cm and 5×8 cm) in the abdominal cavity. As per standard surgical procedure under general anaesthesia, the two tumourous retained abdominal testicles were removed through a paramedian incision on the right ventral abdomen. Torsion of spermatic cord was noticed on the left side which was relieved by rotating it for six times on its axis before removal. The animal had an uneventful recovery. Histopathology of tumour mass revealed Sertoli cell tumour of testicles.

Testicular tumours are the second most common tumours of male dogs after skin tumours. Cryptorchid males have 13.6 times greater risk of developing Sertoli cell tumour than normal males (Mattos *et al*., 2000). Sertoli cell tumour is mostly observed in intact older male dogs. Approximately 70% of Sertoli cell tumours arising in abdominal testes are functional and associated with feminizing paraneoplastic syndrome. Complications due to estrogen induced bone marrow suppression and subsequent pancytopenia has also been reported (DeBosschere and Deprest, 2010).

Retained testes are more susceptible than scrotal testes to spermatic cord torsion and the risk of this condition is increased even more with progressive enlargement of the neoplastic organ. Although closely associated to one another, concomitant occurrence of cryptorchidism, Sertoli cell tumors, feminizing syndrome, spermatic cord torsion and other associated symptoms has been rarely reported in the literature.

Case history and Observation

A 10½ year old male Labrador dog, weighing 25 Kg, was presented to the clinics of the Department of Veterinary Gynaecology and Obstetrics, Veterinary College, Bengaluru with a history of abdominal discomfort, lameness, difficulty in urination and dribbling of urine for a week. Clinical examination revealed bilateral alopecia on ventral abdominal area, hyperpigmentation and gynecomastia (Fig.1). Physical examination revealed bilateral cryptorchidism and large fluctuating masses in the abdominal cavity. The animal was aggressive and elicited pain on abdominal palpation.

Fig. 1. Cryptorchid dog with feminization syndrome

Ultrasonography revealed two large freely moving masses enclosed by a hyperechoic capsule within the abdominal cavity. One round uniformly hypoechoic mass of 5×5 cm size was located just anterior to urinary bladder and another irregular

shaped unevenly hypoechoic mass of 5×8 cm size just posterior to the left kidney (Fig. 2). It was tentatively diagnosed as tumour of retained testicles.

Fig. 2. Ultrasonography picture of abdominal masses

Haematology revealed RBC count of 6.65 millions/µl, WBC count of 14,900/µl, PCV 42 %, Haemoglobin 11.5 g/dl, platelet count of 2,52,000/µl and serum creatinine 1.0 mg/dl.

Based on the symptoms, clinical signs and ultrasonography findings, the case was tentatively diagnosed as Sertoli cell tumour of retained testicles with differential diagnosis of adrenocortical tumour, granulose theca cell tumour and seminomas.

Treatment

It was decided to surgically remove the retained testicles. The dog was premedicated with Inj. Atropine @ 0.04 mg/Kg body wt. subcutaneously and sedated with Inj. Xylazine @ 1 mg/Kg body wt. intramuscularly. Anaesthesia was induced and maintained by Inj. Diazepam and Inj. Propofol (1:1) combination intravenously.

Surgical approach to the abdominal cavity was performed through a right paramedian incision of 10 cm length, between the prepuce and nipples, from the level of preputial opening to backwards. The urinary bladder was exteriorized and identified the vas deferens entering to the prostate gland. The vas deferens was followed cranially and located the retained testicles of both sides. Both the testicles were exteriorized, vascular cord and vas deferens were ligated separately using No. 1 chromic catgut and removed both the testicles. Severe spermatic cord torsion with engorged blood vessels was noticed in the left testicle (Fig. 3). Spermatic cord torsion was relieved by rotating the testis on its axis for six times before ligating and removing the testis. The sublumbar lymph nodes appeared normal. The abdominal incision was closed in three layers as per standard procedure. The animal was treated postoperatively with antibiotics and anti-inflammatory drugs for seven days. The animal had an uneventful recovery with reversion of feminisation symptoms in three months.

On gross examination of the masses, the left was large and irregularly spherical in shape with a thick capsule, measured 5×8×5 cm and weighed 470 g. The right mass was almost spherical in shape with thick capsule, measured 5×5×5 cm and weighed 220 g. The cut surfaces showed yellowish white nodules that almost completely replaced the testicular tissue (Fig. 4). Representative tissue samples were collected, preserved in 10 % buffered formol saline and processed for histopathological studies.

Histopathological studies of the specimens collected from both masses had morphologic characteristics of Sertoli cell tumours, with the densely packed irregular sized neoplastic cell population arranged in irregular tubular structures surrounded by thick fibrous bands. Neoplastic cells were columnar and had round to oval nuclei with irregularly clumped chromatin. There were marked distorsion in testicular architecture

and the cells were arranged in multilayered palisading structures, with their long axes perpendicular to the basement membrane and obliterating the tubular lumen. (Fig. 5).

Fig. 3. Severe spermatic cord torsion with engorged blood vessels

Fig. 4. Abdominal testicles with Sertoli cell tumour and spermatic cord torsion.

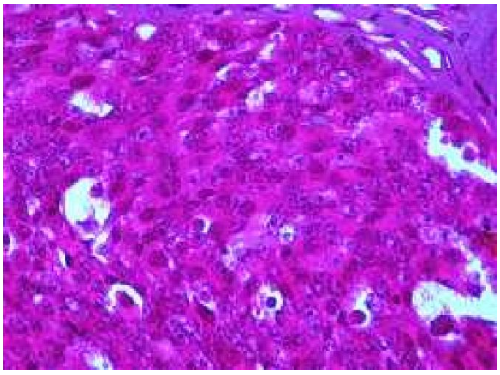

Fig. 5. Microphotograph of Sertoli cell tumour (400X)

Discussion

Cryptorchidism is failure of one or both testes to be positioned in the scrotum at the time normal for a species. Location of undescended testes differs greatly among species, in dogs 92 % of retained testicles were located in the abdominal cavity as also reported by Amann and Veeramachaneni (2006). Complications of cryptorchidism like development of tumour, feminizing syndromes and spermatic cord torsion as also mentioned by Bufalari *et al*. (2015).

Among the various testicular tumours described in cryptorchids, Sertoli cell tumour and seminoma are the most frequently documented tumours in dogs. Sertoli cell tumours are ectopic as also narrated by Suresh Kumar *et al*. (2011); Nair *et al*. (2013) and Navya *et al*. (2013) as well as eutropic testis as mentioned by Banga *et al*. (2009); Quartuccio *et al*. (2012) and Bufalari *et al*. (2015) also. 54.2 % of testicular tumours were noticed in cryptorchids and concluded that cryptorchidism and age factor significantly contributed the incidence and type of testicular tumours in dogs it is in accordnce to Liao *et al*. (2009).

Functional Sertoli cell tumours increases the circulating levels of estradiol and feminizing syndrome will be exhibited, which included gynecomastia, enlargement and thickening of nipples, attraction to other males and female posture urination. The other symptoms included a non-pruritic, bilateral symmetrical alopecia of ventral abdomen, axillary and groin region, hyperpigmentation, edematous and pendulous prepuce, prostatic dysfunctions and weight loss as also reported by Quartuccio *et al*. (2012). Bone marrow suppression and atrophy of contralateral testicles were also there as mentioned by Suresh Kumar *et al*. (2011) also.

Spermatic cord torsion caused ischemia and necrosis of testicles leading to non-specific symptoms like anorexia, abdominal discomfort, lameness etc which

may mislead the diagnosis (Bufalari *et al*., 2015). But in the present case, single sided spermatic cord torsion of tumourous retained testis on its axis for six times was noticed. Symptoms like abdominal discomfort, lameness and pain on palpation of abdomen were also noticed in this case, but grave complications could be prevented by the early intervention of the condition.

Ultrasonography was employed as a useful tool for locating the retained testicles in cryptorchids, but testicular tumours altered its normal structure and were detected as complex abdominal masses it is in accordance to Hong *et al*. (2011). Ciaputa *et al*. (2012) also used ultrasonography to demonstrate the tumour within the ectopic testicles.In the present case also; testicles were located as irregular hypoechoic masses covered by hyperechoic capsule in between the kidney and urinary bladder. The normal appearance of testicle like oval structure with hyperechoic mediastinum testis was absent in the present case due to the presence of tumour. The spermatic cord torsion was also not detected and was identified only during surgery.

Hematological picture altered in Sertoli cell tumour cases mainly due to bone marrow suppression associated with hyperestrogenism. Estrogen myelotoxicosis has been reported in 15 % of dogs with Sertoli Cell tumour and was characterized by bone marrow hypoplasia and non-regenerative anaemia as also reported by Quartuccio *et al*. (2012) and anaemia and leukocytosis as mentioned by Kujur *et al*. (2005). Anaemia with anisocytosis and low platelet count as also narrated by Banga *et al*. (2009) and a moderate non-regenerative normocytic, hypochromic anaemia with leucopenia /neutropenia and severe thrombocytopenia as also mentioned by DeBosschere and Deprest, (2010) were found as haematological alterations in Sertoli cell tumour. In the present study the blood parameters were found normal except for a slight leukocytosis. This indicated that the present case has not persisted for a long time and myelosuppressive effects had not set in.

Histopathology of tumour tissue confirmed Sertoli cell tumour and similar microscopic alterations were described by Grieco *et al*. (2008). Orchiectomy was found to be the treatment of choice employed in all the cases studied it is in accordance to Nair *et al*. (2013) Navya *et al*. (2013) and Bufalari *et al*. (2015) and the animals recovered completely after varying periods.

References

Amann, R.P. and Veeramachaneni, D.N.R. (2006) Cryptorchidism and associated problems in animals. Anim. Reprod., **3(2)**: 108–120.

Banga, H.S., Deshmukh, S., Brar, R.S., Chavhan, S.G. and Gadhave, P.D. (2009) Malignant Sertoli cell tumour in dog – A case report. Indian J. Vet. Pathol., **33(2)**: 229–231.

Bufalari, A., Proni, A., Moretti, G., DiMoe, A. and Pirico, S. (2015) The lameness in a cryptorchid dog with intra-abdominal torsion of one of the two neoplastic testicles: a case report. Vet. Med., **60(8)**: 456–459.

Ciaputa, R., Nowak, M., Bowicz, M., Antonczyk, A., Blasiak, K. and Madej, J. (2012) Seminoma, sertolioma and leydigoma in dogs: Clinical and morphological correlations. Bull. Vet. Inst. Pulawy, **56**: 361–367.

DeBosschere, H. and Deprest, C. (2010) Estrogen induced pancytopenia due to Sertoli cell tumour in a cryptorchid Beauceron. Vlaams Diergeneeskundig Tijdschrift, **79**: 280–284.

Grieco, V., Riccardi, E., Greppi, G.F., Teruzzi, F., Iermano, V. and Finazzi, M. (2008) Canine testicular tumours: a study on 232 dogs. J. Comp. Path., **138**: 86–89.

Hong, S., Lee, H., Han, S. and Kim, O. (2011) Spontaneous Sertoli cell tumor with cryptorchism in a Beagle dog. Lab. Anim. Res., **27(2)**: 177–178.

Kujur, R.F., Priya, S., Balachandran, C., Manohar, B.M. and Rao, G.V.S. (2005) Sertoli cell tumour in a German Shepherd dog. Indian J. Vet. Path., **29(1)**: 54–55.

Liao, A.T., Chu, P., Yeh, L., Lin, C. and Liu, C. (2009) A 12 – year retrospective study of canine testicular tumours. J. Vet. Med. Sci., **71(7)**: 919–923.

Mattos, M.R.F., Simoes-Mattos, L. and

Domingues, S.F.S. (2000) Cryptorchidism in dog. Ciencia Anim., **10(1)**: 61–70.

Nair, S.S., Suresh, L., Nagaraju, N. and Vasanth, M.S. (2013) Surgical management of sertoli cell tumour in a German shepherd dog. Indian J. Vet. Path., **34(1)**: 78.

Navya, M., Sudha, G., Krishna, A. and Krishnaswamy, A. (2013) Sertoli cell tumour in an intact male Swiss mountain terrier dog – a case report. Indian J. Canine Pract., **5(1)**: 26–27.

Quartuccio, M., Marino, G., Garufi, G., Cristarella, S. and Zanghi, A. (2012) Sertoli cell tumors associated with feminizing syndrome and spermatic cord torsion in two cryptorchid dogs. J. Vet. Sci., **13(2)**: 207–209.

Suresh Kumar, R.V., Veena, P., Sankar, P., Lakshmi, N.D., Srilatha and Kokila, S. (2011) Sertoli cell tumors in dogs – A report of four cases. Tamilnadu J. Vet. Anim. Sci., **7(3)**: 154–156.