SURGICAL MANAGEMENT OF PENETRATING ARROW WOUND IN AN INDIAN PARIAH DOG

Jayakrushna Das[1], Biswadeep Jena[2] and Snehasis Pradhan[3]
[1]Associate Professor; [2]Assistant Professor, M.V.Sc. Scholar[3]; Department of Veterinary Surgery & Radiology, College of Veterinary Science & Animal Husbandry, Orissa University of Agriculture and Technology, Bhubaneswar – 751003 (Odisha).
[Received: 29.3.2016; Accepted: 04.10.2016]

Obligation to strict aseptic and immediate surgical interventions resulted in successful management of abdominal, intestinal penetrating arrow wound in a stray Indian Pariah dog.
Keywords: Penetrating wound, Arrow, Enterectomy, Enteroanastomosis, Dog.

The bow and arrow constituted the classical Indian weapon of warfare and hunting. Arrow injury was practically prevalent as it was a one of the most frequently used weapon in ancient India. With passage of time use of bow and arrow became restricted to tribal area mostly to hunting. Effect of injury depends not only on the site of penetration and associated tissue damage, but also to arrow material, associated poison if any and treatment methods. Surgical removal of arrow as early as possible along with appropriate post-operative measures still remains the gold standard of management of such injuries (Srivastava, 2010; Radlinsky, 2013; Ganguly *et al*., 2014). The present communication deals with the successful surgical management of penetrating arrow wound of abdomen and intestines in an Indian Pariah dog.

Case History and Observations

An Indian Pariah dog was presented to the department of Veterinary Surgery & Radiology, College of Veterinary Science & Animal Husbandry, Orissa University of Agriculture and Technology, Bhubaneswar, Odisha with a penetrating arrow injury through right midflank (Fig. 1). On examination, patient was found alert, conscious with elevated heart rate (112/min) and respiration rate (35/min). No pallor, cyanosis, jaundice, clubbing or oedema was present. Pupillary reactions were normal. A three inch long thin bamboo stick found to be emerging out from right mid-flank region. It was moving in sync with respiration. Abdomen was soft, nondistended and diffusely tender, with no rebound tenderness or involuntary guarding. Radiography confirmed presence of a metallic, pointed linear arrow head with sharp barbs at its diagonal notch attached to the thin bamboo shaft emerging out through the right mid-flank region but botched to divulge extent of soft tissue damage. Hence it was decided to perform exploratory laparotomy for removal of arrow and on an emergency basis.

Fig.1. showing penetration of arrow inside abdomen

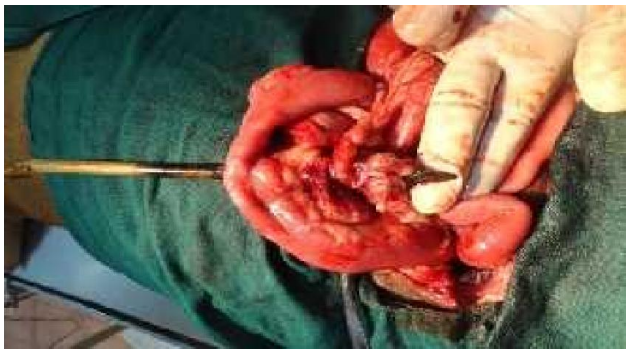

Fig. 2: Showing penetration and entangling of arrow injuring intestine

Treatment and Discussion

The animal was pre-anaesthetised with a mixture of Atropine Sulphate at 0.04 mg/kg body weight and Xylazine hydrocholride at 1 mg/kg body weight administered intramuscularly. After attainment of adequate sedation and smooth muscle relaxation, general anaesthesia was induced and maintained with Ketamine hydrochloride at the dose rate of 5 mg/kg body weight intravenously. The cephalic vein was catheterized and saline-dextrose solution was administered at 10 mL/kg/hr perioperatively. After aseptic preparation of right mid-flank region, two straight skin incisions were given originating from the point of arrow entry in dorsal and ventral direction; incorporating the underlying subcutis, abdominal muscles and peritoneum to expose the peritoneal cavity. Above exploration revealed increased abdominal effusion, entangled arrowhead with intestinal loops along with couple of mesenteric tears and mild ischemic perforated intestinal walls (Fig.2). Arrowhead was removed with utmost care but there was opening up an injured blood vessel which was haemostasized soon, meticulously. After assessing the viability of the affected intestinal loops, it was decided to perfom routine enterectomy and subsequent end to end enteroanastomosis. Peritoneal lavage was performed with normal saline, metronidazole and ciprofloxacin solutions and poole's suction tip was used to suction out excessive abdominal effusion in order to reduce the chance of post-operative peritonitis.

Post-operative care consists of parenteral administration of dextrose fluid therapy, ceftriaxone + tazobactam @ 10 mg/kg body weight and meloxicam at 0.1 mg/kg body weight for 5 days. The normal diet was reintroduced gradually 72 hours after surgery. The patient recovered well without any lasting effects and complications from its surgery.

Arrow injuries, may present with different sets of problem and associated managemental practices. Owing to different designs of arrowhead, it is always safe to have a good dissection of the area before removal of an arrow. The mechanism of injury from sharp pointed and edged objects can be described as having three components i.e., crush, stretch and tear at microscopic level throughout their corresponding path. The penetrating and lacerating injuries caused by arrows depend on the type of arrowhead. In this case a broadhead-tipped arrow was impaled which had made a small crush wound that was enlarged by the blades cutting and separating the soft tissues with substantial haemorrhage evident during exploratory laparotomy and removal of entangled arrowhead.

In order to avoid long standing complications like septicaemia, peritonitis, delayed wound healing, chronic pain syndrome, permanent disfigurement and contractures; it was decided to perform exploratory laparotomy and proper wound toileting to remove arrowhead surgically on an emergency basis.

Sometimes some herbal extracts or animal secretions are smeared over arrowheads to inflict supplementary injuries via poisoning. Although initially we were unsure about use of any arrow toxin but later on absence of any significant systematic complication in conjunction with full clinical examination with special emphasis to central nervous system and examination of pupil, rectified our confusion.

During detangling of the arrowhead from the intestinal loops and mesentery precipitated few bleeders, which were previously absent due to pressure exerted from the arrowhead. After retrieval of occult arrowhead, couple of larger intestinal and mesenteric tears with circumferential necrotic lesions were evident. Eneterectomy followed by end-to-end enteroanastomosis were performed to correct above defects. Simple mural haematomas were oversewn with a simple continuos inverting lembert suture pattern.

As patient being admitted within 6 hours of injury in concomitant with vital parameters within normal range, position of the arrow had laid a strong foundation of its survivality as also reported by Mayhew and Culp (2011); Paramhans et al, 2010; Peloponissios *et al.* (2001); Radlinsky (2013).

Acknowledgements

The authors are thankful to the Head, Department of Veterinary Surgery & Radiology, College of Veterinary Science and Animal Science, Orissa University of Agriculture and Technology, Bhubaneswar, Odisha for his support and cooperation in carrying out the study.

References

Ganguly, T., Kar, S.K., Dasgupta, C.S., Goswami, A., and Mandal, A. (2014) Penetrating Arrow Wound of the Chest-A Case Report. J. Case Rep. Stud., **2(5)**: 1-6.

Mayhew, P.D. and Culp, W. (2011) Trauma-associated gastrointestinal injury In: Drobatz, K.J., Beal, M.W., & Syring, R.S. (Eds.). Manual of trauma management in the dog and cat. 1st Edn., John Wiley & Sons, The Atrium, Southern Gate, Chichester, West Sussex, U.K. Pp.220-228.

Paramhans, D., Shukla, S., Batra, A., and Mathur, R.K. (2010) Successful removal of an impacted metallic arrowhead penetrating up to the brainstem. Journal of Emergencies, Trauma and Shock, **3(3)**: 303.

Peloponissios, N., Halkic, N., Moeschler, O., Schnyder, P., & Vuilleumier, H. (2001) Penetrating thoracic trauma in arrow injuries. The Annals of Thoracic Surgery, **71(3)**: 1019-1021.

Radlinsky, M.G. (2013) Surgery of the Digestive System. In: Fossum, T. W. (Ed). Small animal surgery, 4th Edn., Elsevier Health Sciences, St. Louis, Missouri,U.S.A. Pp.497- 516.

Srivastava, A.K. (2010) Surgical Management of Traumatic Pneumothorax in a Siamese cat. Journal of Canine Development & Research, **6**: 108-110.