ULTRASONOGRAPHIC PREGNANCY DIAGNOSIS AND LANDMARKS IN DOMESTIC CATS

S.U. Gulvaane, M.N. Rangnekar, S.A. Bakshi, R.J. Chaudhari and P.J. Thakur
Department of Animal Reproduction, Gynaecology, and Obstetrics,
Bombay Veterinary College, Parel, Mumbai -12.
[Received: 28.2.2014; Accepted: 08.6.2014]

Twenty two queens of Persian breed were divided into two groups depending on the history of mating. Group A (n = 13) queens had confirmed history of mating and Group B (n = 9) queens had unknown history of mating. The queens were scanned below day 40 {A(I) and B(I)} and above day 40 {(AII) and (BII)} of gestation. A real time, B mode, portable ultrasonographic machine (SSD – 500 Aloka Co.Ltd., Japan) with 3.5 MHz transabdominal sector transducer was used for scanning of the uterus. All the queens were scanned 20 days and above to avoid false negatives. In group A (I) and B(I) the gestational sacs were visible on day 20 when the study was started, with a C-shaped embryo. Other landmarks like cardiac activity, ossification, movements of embryo were observed on day 20, 32 and 35, respectively. In group A (II) and B (II) biparietal diameter and body diameter were measured as the head was distinctly observed and the rib cage was also seen. Foetal structures like stomach, eye was observed on day 47 and 42 respectively whereas, pronounced foetal movements were observed from day 44. The different chambers of the heart with valve movements were observed at day 53.
Keywords: Cats, Ultrasonography, Pregnancy, landmarks

Introduction

Cat breeding is a growing field but there is limited data available on breeding, pregnancy diagnosis, queening and other reproductive indices. No method is commercially available to assess the feline physiologic response during pregnancy. Behavioral changes seen in queens during metestrus do not allow differentiation between pregnancy and pseudopregnancy following fertilization failure. The detection of pregnancy by abdominal palpation can usually be performed in a tractable individual at around 30 gestational days. Much greater manual skills are required for earlier detection of pregnancy. Radiographic studies of the pregnant queen become reliable only after skeletal ossification begins, generally from 35 to 39 days of gestation. Pregnancy diagnosis by abdominal palpation or radiography may confirm the presence of foetuses at one point in time, but these methods cannot be used to assess foetal viability until profound morphologic changes have occurred (Davidson *et al*., 1986). Hence, the present study was conducted to perform ultrasonographic pregnancy diagnosis in domestic cats and study the foetal landmarks during gestation at different phases.

Materials and Methods

Total twenty two clinically healthy queens of Persian breed aged between 1.5 to 6 years and weighing around 1.5 to 3 kg were scanned between 20 to 60 days post mating in the Department of Animal Reproduction, Gynaecology and Obstetrics, Bombay Veterinary Collage, Parel, Mumbai 400 012 and private clinics located in Mumbai. All the scans were performed 20 days and above to avoid false negatives. The queens were divided in to two groups as follows: Group A (n= 13): in this group, queens had confirmed dates of mating recorded by the owner. Group B (n=9): In this group, queens had history of mating but dates of mating were unknown or not recorded by the owner.

The queens in Group A were further divided into two groups depending on the stage of gestation in which they were scanned. Thirteen queens were scanned in Group A (I) below day 40 of gestation and these thirteen queens were scanned again above day 40 of gestation in Group A (II).

Group A (I): 13 scans less than day 40 of gestation.
Group A (II): 13 scans above day 40 of gestation.

Group B had nine queens in total, of which six queens were scanned in Group B (I). One queen (K2) was scanned twice in Group B (I). Therefore, the total number of scans in Group B (I) was seven. Eight queens were scanned in Group B (II), of which three queens were scanned twice in Group B(II). Therefore, the total number of scans in Group B (II) was eleven. The queens from Group B were further divided in to two groups depending on the stage of gestation in which they were scanned.

Group B (I): 7 scans less than day 40 of gestation.
Group B (II): 11 scans above day 40 of gestation.

A real time, B mode, portable ultrasonographic machine (SSD-500 Aloka Co. Ltd., Japan) with 3.5 MHz transabdominal sector transducer was used for scanning of the uterus (Plate 1). The full bladder was used as an acoustic imaging window to locate the uterus. The selected queens were prepared by clipping the hair on the ventral abdomen. Queens were held in the dorsal recumbency (Plate 2) for better ultrasonographic image.

Plate 1: Ultrasonography machine with attached thermal printer

Plate 2: Restraining of the queen in dorsal recumbency

Results and Discussion

Group A (I) and B (I)

Pregnancy diagnosis using ultrasound and landmark observed before day 40 of gestation:

In this group 14 queens were scanned of which 13 were diagnosed pregnant and one queen was diagnosed as non-pregnant. From the 13 pregnant queens measurements of 35 foetuses and 38 gestational sacs were taken. Pregnancy was confirmed after the anechoic gestational sacs were visible on the screen of the ultrasound machine. These anechoic gestational sacs were circular to ovoid in shape and were surrounded hypoechoic to hyperechoic wall of the gestational sac. In the present study, the gestational sacs were visible on day 20 of gestation in one queen (C10) who was scanned at that time. Other queens were scanned above twenty days of gestation depending on their availability. Davidson *et al* .(1986), Pineda (1989), Grifin (2001), Baker *et al*. (2002), Matton and Nyland (2002), Zambelli *et al*. (2002a) , Zambelli *et al*. (2002 b) , Tibary *et al*. (2003) , Dickie (2006) and Zambelli *et al*. (2006) recorded earliest pregnancy diagnosis after 10th day post breeding (day 11- 14). Their findings could not be compared with the findings of the present study as the scanning in the current study commenced from 20th day of gestation to avoid false negatives. The observations were taken from 20th day of gestation considering the findings of Burke *et al*. (1986) who found that it was difficult to get correct observations with real time units prior to 18 day of gestation.

In the present study, the embryo was visible at day 20 as a 'C' shaped structure. This 'C' shaped structure was maintained till day 24. Zambelli *et al*. (2002b) and Zambelli *et al*. (2006) found a well defined embryo after day 18 which was in accordance with the present findings. Matton and Nyland (2002) observed the embryo later by day 23 to 25 as compared to the findings of the present study. Similar to the present study, Dickie (2006) first observed the embryo on day 21 of gestation. In the present study, the embryo was not attached to the gestational chamber when first observed at day 20. It appeared as a mass separated from the wall of the sac and folded on itself. At day 24 the embryo appeared straight as compared to the observation on day 20, 22 and 23. The embryo appeared elongated and parallel to the gestational chamber on day 28 of gestation. Similar observations were recorded by Zambelli *et al*. (2002b) who observed the longitudinal axis of the embryo parallel to that of gestational chamber after day 26.

In the present study, all the embryos seen showed cardiac activity 20th day onwards. From day 20 to 24 the cardiac activity was observed as flickering movements with changing echogenecity. A properly beating heart was seen beyond day 25. However, different chambers of the heart were not observed at this stage. These findings were similar to Davidson *et al*. (1986) , Matton and Nyland (2002) , Zambelli *et al.* (2002b), Verstegen (2005) , Zambelli *et al*. (2006) and Kustriz (2010). Tibary and Memon (2003) recorded fetal heart beats between day 16-20 which was slightly earlier than the present study. However, in the present study observations were not taken before day 20.

In the present study, differentiation of limb buds and head was observed on day 28. However, they were more prominent with foot pads after day 35. This finding was in accordance with Davidson *et al*. (1986), Tibary and Memon (2003), Matton and Nyland (2002). Zambelli *et al*. (2002 b) recorded the appearance of limb buds much earlier by day 17, which was not in agreement with the present study. This difference in the observation might be due to higher resolution of new age machines and probe frequencies used by these workers. However, they observed foot pad from day 35, which was similar to the present finding.

In the present study, the ossification had started from day 32 with the spinal cord being faintly visible at day 35. The margins of the head were also visible from day 33 onwards. These findings were similar with that of Burke *et al*. (1986) who measured the biparietal diameter of the skull from day 35 onwards. Matton and Nyland (2002) observed foetal skeleton from day 33 to 39. Movements of the embryo like dorso-ventral flexion were observed on day32 whereas the limb movements were observed from day 35. These findings were similar to Zambelli *et al*. (2002 b), Matton and Nyland (2002) and Tibary and Memon (2003).

Group A(II) and Group B(II)

Pregnancy diagnosis using ultrasound and landmarks observed during gestation after day 40:

In this group, a second scan of queens C1 to C13 from group A (I) was performed above day 40 of gestation. All 13 queens were confirmed to be pregnant on second scan. One queen who was found to be non-pregnant at day 23 was scanned again after 20 days and was found to be non-pregnant. During this phase some landmarks of foetal development were studied. After day 40, foetuses were easily detected due to complete ossification. Hence, biparietal diameter and body diameter were measured as the head was distinctly observed and the rib cage was also seen. In this stage, gestational sacs were more elongated. The foetuses were active and cardiac activity was distinctly visible. During this phase foetuses became

thicker and more oblong. The zonary placenta became apparent in the middle of the vesicles, seen as finely granular structure of moderate echogenecity. As the foetal age progressed, foetus started occupying more of lumen of the gestational sacs. It was difficult to visualize single gestational sac with complete foetus during this phase.

The amount of foetal fluid was less and fetuses did not float inside gestational sacs from day 50 and were in close contact with uterine wall. Foetal fluid was seen only cranially and caudally to the foetus. The foetal vertebrae were visible in all the fetuses. Jaw movements of the fetus were seen at some occasions beyond day 50. Inside foetal abdomen, anechoic area was observed in the area of the stomach. By day 44, cross section of foetal ribs was visualized. Anechoic structures was seen towards the end of the rib cage which was identified as the stomach at around day 47. Zambelli *et al*. (2002b) had identified stomach dorsal to the liver by day 30 and caudal to the liver by day 49. Their findings were almost similar to the present findings. Pronounced foetal movements were observed from day 44. The movements of the foetal head, limbs and neck were prominent with dorso- ventral flexion of the foetus. In the present study, eye was observed around 42nd day which was slightly late than the observations recorded by Zambelli *et al*. (2002 b) and Zambelli *et al*. (2006). In the present study, the mouth and tongue movements were recorded after day 50. This finding was in accordance with Zambelli *et al*. (2002 b). It was possible to measure the heart beats using the different (B/M) mode on the ultrasound machine (Plate 3). The foetal heart beat ranged from 220 to 280 beats. The different chambers of the heart with valve movements were observed on day 53, which was similar to observation made by Zambelli *et al*. (2002 b) and Zambelli *et al*. (2006).

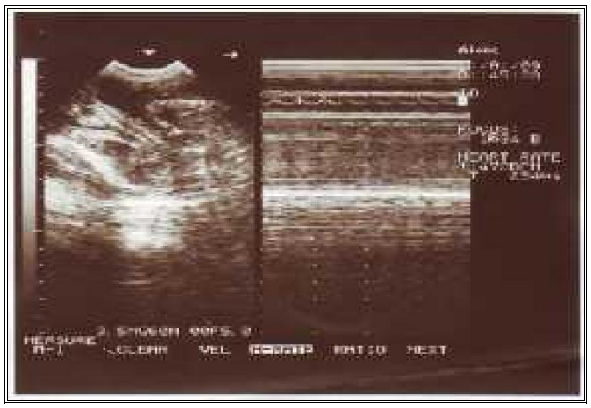

Plate 3: Heart rate of the foetus on B/M mode

In conclusion, gestational sacs were visible above day 20 to confirm pregnancy with a presence of C- shaped embryo. Other landmarks like cardiac activity, ossification, movements of embryo were observed on day 20, 32 and 35, respectively. Whereas, when scanned above day 40 of pregnancy, biparietal diameter and body diameter were measured as the head was distinctly observed and the rib cage was also seen. Foetal structures like stomach, eyes were observed on day 47 and 42, respectively whereas pronounced foetal movements were observed from day 44. The different chambers of the heart with valve movements were observed at day 53.

References

Baker, T. and Davidson A. (2002). Reproductive ultrasonography: The Bitch and the Queen with case studies, 81st western veterinary conference:

255-258.
Burke, T. J. and Badertscher R. R. (1986). Pregnancy diagnosis in: small animal reproduction and fertility. A clinical approach to diagnose and treatment. Lea and febiger, Philadelphia: 85-92.
Davidson A. P., Nyland T. G and Tsutsui T. (1986). Pregnancy diagnosis in small animal practice, Blackwell Publishing, UK. Ch **8**: 145-169.
Dickie, A. (2006). Imaging of the reproduct -ive cat in: Diagnostic ultrasound in small animal practice, Blackwell Publishing, UK. Ch **8**: 145-169
Griffin, B. (2001). Prolific cats: The estrus cycle. Compendium **23(12)**:1049-1055.
Kahan, W. (1994). Ultrasonography in dogs and cats in: Veterinary reproductive ultrasonography. Mosby wolfe, Germany: 227-249.
Kustriz Root, M.V. (2010). Feline tchnique -s in: Clinical canine and feline reprod- uction: evidence- based answers, 1st ed. Wiley Blackwell, lowa **59**: 191-192s
Matton and Nyland (2002). Ovaries and uterus in: small animal diagnostic ultrasound, 2nd ed. Saunders, Philadelphia: 231-249.
Mantis (2008) Ultrasonography of the urinary and genital system in the dog and cat. Iranian Journal of Veterinary Surgery (suppl): 63-71.
Pineda, M.H. (1989). Reproductive patterns in domestic cat in veterinary endocrinology and reproduction. 4th ed. Lea and Febiger, Philadelphia:487-502.
Tibary, A. and Memon M. (2003). Pregnan -cy in: the practical veterinarian-Small animal theriogenology. Elsevier scienc -e,United States of America **8**:207-240.
Verstegen J. (2005). Feline reproduction in textbook of Veterinary Internal Medicine Vol.2.5th ed. W.B. Saunders, Pennsylvania:1585-1599.
Zambelli, D. , Castagnetti C. , Belluzzi S. and Bassi S (2002a). Correlation betwe -en the age of the conceptus and variou -s ultrasonographic measurements during the first 30 days of pregnancy in domestic cats (feli catis). Theriogenology **57**: 1981-1987.
Zambelli, D. , Caneppele B. , Bassi S. , Paladini C. (2002b). Ultrasound aspect -s of fetal and extra fetal structures in pregnant cats. Journal of feline medicine and surgery **4**: 95-106.
Zambelli D. , and Prati F. (2006). Ultrasonography for pregnancy diagnosis and evaluation in queens. Theriogenology **66**: 135-144.

*****