DIAGNOSTIC AND THERAPEUTIC MANAGEMENT OF CANINE OSTEOARTHRITIS

V.P. Chandrapuria[1], Apra Shahi[2], H.S. Dhakare[3] and Somil Rai[4]
[1]Professor & Head, [2]Associate Professor, [3]M.V.Sc.Scholar, [4]PhD.Scholar, Department of Veterinary Surgery and Radiology, College of Veterinary Science and A. H., Jabalpur.
[Received: 27.12.2013; Accepted: 20.5.2014]

Osteoarthritis is the most common orthopedic disease causes of lameness in dogs. The destructive changes that lead to osteoarthritis are irreversible. The present study was conducted on eighteen dogs which were clinically examined, 8 were found with mild lameness of hind limb, 6 showed moderate lameness while 4 showed severe and debilitating lameness. Anamnesis and clinical signs including severity, debility, muscle atrophy, wobbling gait, changes in body conformation, vocalization and pain on flexion and extension and cripitus of the joint, were consistent with severe form of the disease. The radiographic finding at day 0 showed mild periostitis, subchondral sclerosis, irregular joint space, osteophyte particularly at cartilage margins and rough definition of joints. On 14th day, sub-chondral sclerosis reduced with distinct articular margin and osteophytosis also subsequently reduced on 21, 40 and 70 post observation day. Synovial fluid examinations showed significant changes in turbidity, viscosity and cell count in group III followed by group II and I, respectively. Glucosamine and chondroitin sulphates combination was found chondro-protective with the recovered radiographic changes from osteoarthritis at different intervals in all the groups.

Introduction

The most common form of canine arthritis is Osteoarthritis and is also one of the most common causes of lameness in dogs. It is caused by deterioration of joint cartilage, followed by pain and loss of range of motion of the joint. Cartilage is a smooth, resilient tissue that lines the joints, allowing nearly frictionless joint movement, and providing shock absorption. Disruption of cartilage leads to increased friction and inflammation in the joints. This erodes the bone and can cause formation of new bone, called osteophyte (bone spur) which interferes with normal joint movement and can cause pain and other complications.

Diagnosis of osteoarthritis is made primarily on the basis of history, clinical signs, radiography, arthrography and synovial fluid analysis radiographs may demonstrate joint effusion, osteophyte formation, subchondral sclerosis and bone remodeling (Morgan *et al.,* 1987). The class of drugs most commonly used for pain control in canine osteoarthritis is the non-steroidal anti-inflammatory drugs. Acetaminophen is the first drug recommended for mild to moderate osteoarthritis. Commonly used NSAIDs are aspirin, ibuprofen, naproxen ketoprofen, piroxicam and meloxicam. Intra-articular injection of sodium hyaluronate (i.e., hyaluronic acid [HA]. Hyaluronan). Also referred to as viscosupplementation, has been shown to be safe and effective for the symptomatic relief of knee OA. The chondroprotective agents, counter arthritic degenerative processes and encourage normalization of the synovial fluid and cartilage matrix (Iwata, 1993).

Materials and Methods

The study was conducted on 18 clinical cases of osteoarthritis in adult dogs of either sex, presented at Department of Veterinary Surgery and Radiology, TVCC, College of Veterinary Science and A.H., N.D.V.S.U., Jabalpur having signs of osteoarthritis. In positive dogs, radiography, arthrography and synovial fluid analysis were carried out for differential diagnosis of osteoarthritis from aseptic arthritis, inflammatory arthritis,hip dysplasia, sprain and strain, joint dislocation and fracture.

Eighteen dogs of either sex suffers from osteoarthritis were divided equally into three groups and supplemented with glucosamine and chondroitin sulphate 500–

1,500 mg daily orally for 30 days. Six animals of first group were treated with Inj. Meloxicam at the dose rate of 0.2 mg/kg Body wt. Intramuscular for 5 days followed by tablet meloxicam orally for next 5 days at dose rate of 0.2 mg/kg Body Wt. daily.

RADIOGRAPHIC FINDINGS:

Figure 1: Periostitis, mild Subchondral sclerosis with rough definition of joint margin in Group I, Day 0 (Stifle joint)

Figure 2: Mild sclerosis, improved joint margin in Group I, Day 70 (Stifle joint)

ARTHROGRAM:

Figure 3: Median pooling of contrast agent

Figure 4: Injuries in articular cartilage, narrowing of joint space, cartilage fissuring and fragmentation

Second group were treated with inj. Meloxicam at the dose rate of 0.2 mg/kg Body wt. intra muscular for 5 days followed by tablet meloxicam orally for next 5 days at dose rate of 0.2 mg/kg Body Wt. daily and along with therapeutic ultra sound for two to four week.

In group third, six animals were treated with intra articular injections of hyaluronidase (inj. Hynidase 1500 IU)three to five times at weekly intervals by taking all aseptic measures during procedure.

Radiograph of the animals were taken in dorso-ventral and lateral view on 0, 14th, 21st, 40th and 70th day to look for signs of increased joint fluid, bone hardening and new bone formation. Contrast radiography was done for diagnosis of osteoarthritis; articular cartilage joint capsule and sac were evaluated with the technique. Synovial

fluid samples were collected in all cases with OA by arthrocentesis after following all aseptic precaution.

ARTHOCENTESIS

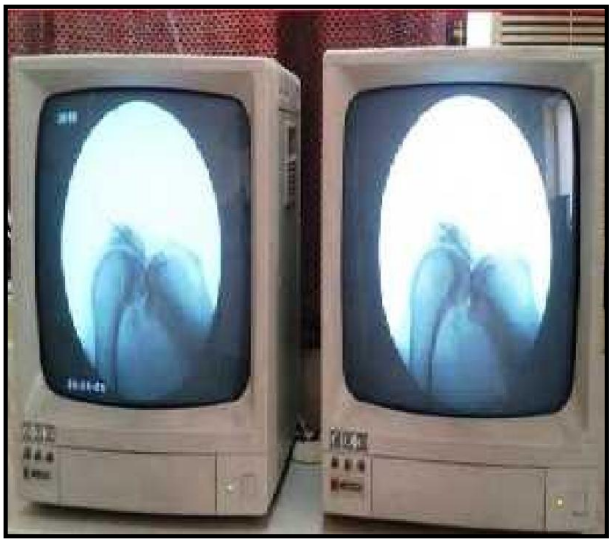

Figure 5: Collection of synovial fluid from stifle joint Figure 6: Collection of synovial fluid from stifle joint (C- Arm Image)

Results and Discussion

During one year period total 12600 cases of various disciplines were presented at TVCC. The joint disorder was recorded in 720 cases and the prevalence was 5. 71%. Out of joint disorders, osteoarthritis was recorded in 220 cases with the prevalence of 30.55% and the overall prevalence of osteoarthritis was noticed 1.75%. The highest prevalence of joint disorders observed in age group of 12-15 years. Eighteen dogs recruited in the present study were clinically examined and none was found clinically normal, 8 were found with mild lameness of the hind limb, 6 showed moderate lameness while 4 showed severe and debilitating lameness.

The animals of groups I and II showed significant reduction in lameness on day 7 and total recovery on day 21. The efficacy of meloxicam with therapeutic ultrasound was noticed better than meloxicam alone or intra articular injection of hyaluronidase. Group III animals showed a decrease in grading score of lameness on day 21 which further reduced significantly by day 45 of observation periods.

At day 0 out of eighteen dogs the radiographic features of 8 dogs showed slight narrowing of joint space and possible osteophyte, mild periostiitis, rough density and definition or joint margin, indicative of mild osteoarthritis. In six dogs the narrowing of joint space was clearly evident with osteophytosis and slight subchondral sclerosis concentrated at center of articular margin. In rest of the four dogs the joint space narrowing, subchondral sclerosis, osteophytosis and slight rough flattened articular margin with irregular bone formation at places were the prominent radiographic features. The large osteophytes were also visible at few places. Mazzuca(1999) observed joint space width measurement for the diagnosis of osteoarthritis Vasseur *et al.*(1992) stated that osteophyte is characteristic abnormality of osteoarthritis. Subchondral bone changes that accompanied osteoarthritis include eburnation, cyst formation, flattering and deformity as observed by Morgan(1969). These changes predominate in areas of the joint subjected to increased load bearing (Marshal, 1969).

The arthrographic findings were absent in eight animals, doubtful in six and characteristics in four dogs. It included roughning of articular cartilage and narrowing of joint space with irregular bone surfaces. These four dogs were also diagnosed with severe osteoarthritis by radiographic findings and clinical examination. The arthrographic findings of the present study were similar to the report of Dalinka *et al.* (1977), Andren and Lundberg (1965) and Poulos(1982).

In the present study synovial fluid analysis revealed change in turbidity, viscosity and cell count while other parameters were almost normal in all the various groups. Arthrocentesis and synovial fluid analysis are useful in confirming the non inflammatory or mildly inflammatory nature of osteoarthritis and in ruling out septic, immune-mediated, acutely traumatic, or neoplastic processes. It is claimed to be the best method to diagnosed and monitor degenerative diseases however synovial fluid analysis alone cannot always differentiate osteoarthritic joints from healthy one. Synovial fluid color, turbidity, and viscosity can be easily assessed at the time of collection or when the sample is expelled onto a glass slide (Parry 1999). Synovial fluid from inflammatory joints shows variable discoloration and decreased viscosity. Discoloration may be because of pleocytosis and decrease in viscosity caused by a deficiency of polymerized hyaluronic acid or a dilution from excess serum. (Hopper, 1993) Synovial fluid was noted to be either colorless, yellow tinged, hemorrhagic, aqueous or viscous in dogs of the three group in present study.

Glucosamine and chondroitin sulphates combination was found to suppress the hematological parameters slightly in all the groups however its chondroprotective property has been proved with the recovered radiographic changes from osteoarthritis at different intervals in all the groups.

References

Andren, L. and B.J. Lundberg (1965). Treatment of rigid shoulders by joint distention during arthrography . *Acta Orthop scand.,* **36** : 45.

Dalinka, M.K.,R. E. Brennan and C. Canino (1977). Double contrast knee Arthrography in Children. *clin. Orthopaedics &related res.,***125**: 88-93.

Hopper, P. E. (1993). Immune-mediated joint diseases. *In:* Textbook of small Animal Surgery (ed.2) Slatter D. Philadelphia, pp. 1928-1937.

Iwata, H. (1993) Pharmacologic and clinical aspects of intraarticular injection of *hyaluronate.Clin orthop.,***28**: 285-301.

Marshal J. l. (1969). Periarticular osteophyte initiation and formation in the knee of the dog. *clin orthop.,* 62: 37.

Mazzuca, S. A., (1999). Field test of the rep -roducibility of automated measurements of medial tiofemoral joint space width derived from standardized knee radiogra -phs. *J Rheum.,* **26**(6); 1359-1365.

Morgan J. P. (1969). Radiological patholog -y and diagnosis of degenerative joint disease in the stifle joint of the dog. *Journal of small animalpractice,* **10**:541.

Morgan, J. P., R. R. Pool and T. Miyabayasi (1987). Primary degenerative disease of shoulder. *J. Am Vet Med* assoc., **190**: 531.

Parry, B. W. (1999). S ynovial fluid analys -is. *In:* Diagnostic Cytology and Hemato -logy of the Dog and Cat (ed.) Cowell R. L., R.D. Tyler, and J. H. Meinkoth , Mosby, pp. 104-119.

Poulos, P. W. (1982). Canine osteochondrosis. *Vet. Clin North Am Small Anim Pract.,* **12**:313.

Vasseur, P.B., H. D. Egryse and B. Vanryssen (1992). Progression of stifle osteoarthrosis following reconstruction of the cranial cruciate ligament in 21 dogs. Journal of the American animal hospital association, **28**:129.