A CASE OF CANINE TRANSMISIBLE VENEREAL TUMOUR IN A MALE DOG AND ITS SURGICAL MANAGEMENT

Jayakrushna Das[1], Sidhartha Sankar Behera[1], S.K. Panda[2], P.K. Rath[2], M. Behera[2] and S. Pati[2]

[1]Department of Veterinary Surgery and Radiology, [2]Department of Veterinary Pathology, [3]Department of Veterinary Biochemistry, College of Veterinary Science and Animal Husbandry, OUAT, Bhubaneswar, Odisha, 751 003, India.

[Received: 13.12.2013; Accepted: 25.5.2014]

Introduction

Tumours of the reproductive organs are common (Slatter, 2003). But tumours of the penis and prepuce are fairly common in the horse, mule, ass and dog (O' Connor, 2005). Canine transmissible venereal tumour (CTVT) is a neoplasm of external genitalia in dogs transmitted by the physical transfer of viable tumour cells by direct contact with injured skin and/or mucous tissue. These cells can transpose across histocompatibility barriers into unrelated hosts (Stockmann *et al.,* 2011). It is most common during the period of maximum sexual activity in dogs and the animals are particularly at highest risk when females exhibit the signs of oestrus. Dogs of any breed, age or sex are susceptible (Kimeto and Mugera, 1974; Betamuzi, 1992). Although dogs over one year of age are at high risk in endemic areas, but is most common in dogs of 2 to 5 years old (Higgins, 1966; Pandey *et al*., 1977). This CTVT comprise papillomata, fibromata, sarcomata, melanomata, myxomata, adenomata, carcinomata and cysts (O' Connor, 2005) and also known by various names such as stickers tumour, venereal granuloma, canine condyloma, transmissible sarcoma, transmissible lymphosarcoma, histosarcoma and so on. This affects the external genitalia and is transmitted from animal to animal through sexual contacts but may also occurs by dog bites, sniffs or licks the tumour affected areas (Bloom, 1954; Das *et al*., 1989; Khan *et al.*, 2009).

Case history and Clinical Observations

A 4 years old male non-descript dog weighing 27 kg body weight was presented at Department of Veterinary Surgery and Radiology, C.V.Sc. and AH, OUAT, Bhubaneswar with complaint of tenesmus during urination, dribbling of urine with serosanguineous discharge, sniffing and leaking to the genital area and unable to retract the penis inside prepucial sheath (Fig.1). All the clinical parameters recorded like rectal temperature (102^0 F), respiration rate (20/min.), heart rate (80/min) were within the normal range. Suspecting it for urolithiasis it was examined under C-arm but no finding about urinary calculi was observed. On clinical examination multilobular mass on base of penis mucosa was found. Previously there was history of occurrence of the same type tumour in that area. Tentatively it was diagnosed as CTVT and decided for surgical correction.

Surgical procedure

After a routine preoperative fasting the dog was premedicated with mixture of Atropine sulphate @ 0.04 mg/kg body weight, Xylazine hydrochloride @ 1 mg/kg body weight and Ketamine hydrochloride @ 5 mg/kg body weight in cocktail mixture intramuscularly. The anaesthesia was maintained with a top-up using Ketamine hydrochloride through the venous port used for normal saline solution (NSS). The dog was restrained on lateral recumbency and the upper hind limb was tied to operation table in elevated manner for convenience.

The operation site was routinely prepared aseptically for surgery. By retraction of the prepucial sheath, the penis was protruded encircling the base of penis (Fig. 2). and it showed large cauliflower like masses

Fig.1. Protrusion of penis with cauliflower like growth at the base

Fig.2. Preparation of site for surgery

Fig.3. Excision of tumour mass by introducing naso-gastric feeding tube in to urethra

Fig.4. Excised tumour mass

Fig.5. Suturing of damaged mucosa

Fig.6. Reposition of penis inside the prepucial sheath

A nasogastric feeding tube was introduced into the urethral orifice and the multi lobulated cauliflower like masses were excised carefully without affecting the penis (Fig. 3,4). During excision some portion of mucus membrane was injured and still some mass was remained at the base of the penis. As the tumour mass was closely attached to the base, so it was not possible to reach at that part by simple retraction of the penile sheath. Hence the site was cauterized with silver nitrate stick and simultaneously neutralizing with normal saline. The incised edges of the penile mucous membrane were sutured with chromic catgut no 2-0 with needle (Fig.5). Terramycine topical lotion was instilled at the site and inj. Adrenaline was

sprayed to control capillary bleeding and then the penis was released into the sheath after fixing a nasogastric feeding tube to the wall of the prepuce (Fig.6). Post-operatively the dog was treated with inj. of Ceftriaxone @ 10 mg/kg body weight for 7 days, inj Meloxicam @ 0.2 mg/kg bodyweight for 3 days. The prepucial sheath was flushed daily with topical antiseptic lotion with a 2 ml syringe for a week. For complete removal of the left over portion of tumour mass at the base, chemotherapy was decided to use. It was achieved with inj. of Vincristine sulphate @ 0.025 mg/kg body weight with 10% dextrose solution weekly once for 3 weeks. During that period the dog was monitored properly and nutrious food, multivitamins and liver tonics were recommended to eliminate the stress. The tissue sample was sent for histopathological examination.

Results and Discussion

The histopathology of the tissue sample showed round and oval cells having fine granular acidophilic cytoplasm and large hyperchromatic nucleus with fine connective tissue stroma, which was suggestive of venereal granuloma (Fig.7). The dog showed normal

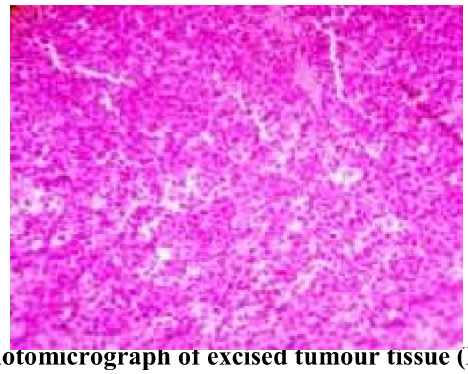

Fig.7. Photomicrograph of excised tumour tissue (H & E X 400)

urination without any difficulty after 10th day of operation when the catheter was removed. There was no serosanguinous discharge from the prepucial sheath. The owner was advised to avoid mating and not to allow outside for mixing with other dogs. Generally the CTVT occurs naturally on the genitals of both male and female dogs. In male dogs it is located on the penis or praeputium and in females it is present on the vagina or labia. CTVT has cauliflower-like shape and it could be pendular, nodous, papilar or multilobular (Das and Das, 2000). Usually the pet owner encounters the problem when the pets are in suffering stage. At the initial stage if those can be presented simply with chemotherapy can solve the condition. But in delayed case both surgical and chemotherapy are needed which have occurred in the present case. The CTVT which has the highest percentage of incidence in canines but still the cause is obscure. Some opined it as viral origin while others as C type of virus like particle associated with CTVT (Khan et al., 2009). In these the metastasis is rare occurring in less than 5-17 % of cases (Richardson, 1981; Rogers, 1997) but is reported to be high in puppies and immune compromised dogs (Yang, 1988). According to O' Connor (2005) complete surgical excision is the choice for treatment. Regarding chemotherapy three consecutive injection of Vincristine sulphate @ 0.025 mg/kg body weight once weekly for 4 weeks by slow I/V route revealed promising result (Athar et al., 2001; Barragry, 1994; Ganesh et al., 1993; Khan et al., 2009). But the present case was with acute problem in dribbling of urine and feeling much pain while urination, so surgical excision was adopted. When the tumourous mass are very numerous, successive operations at intervals of a week may be necessary and when there lies suspicion of recurrence in

the operation case, the latter should be cauterised with silver nitrate (O' Connor, 2005). In this case owing to the close adherence to the base, so was cauterized with silver nitrate. Here the dog was followed for six months and there was no sign of recurrence.

References

Ather, A., Suhail, A., Muhammad, G., Shakoor, A. and Azim, F. (2001). Clinico-therapeutic studies on canine transmissible venereal tumour. Pakistan Vet. J. **21 (1)**: 39-43.

Barragry, T. B. (1994). Veterinary drug therapy. Lea and Febiger, Philadelphia.pp.919-39.

Betamuzi, E.K. (1992). Risk factors associ-ated with canine TVT in Tanzania.Preve -ntive Veterinary Medicine, **13**: 13-17.

Bloom, F. (1954). Pathology of dog and cat. American veterinary publication Eastern Illinois. Pp. 275.

Das, A.K., Das,U., Das,D.K. and Sengupta, J.(1989). Metastasis of canine transmissi -ble of venereal sarcoma in a dog. Ind. Vet. J. **10 (1)**: 74-75.

Das, U. and Das, A.K. (2000). Review of canine transmissible venereal sarcoma. Veterinary Research Communications, **24 (8)**: 545-556.

Ganesh, T.N., Kumar, B.R., David, W.P.A. Balasubramanian, N.N., Pattabiraman, S.R. and Mohammed, M.S.D.M. (1993). Clinical trial on the effect of Vincristine on transmissible venereal tumours in dogs. Indian Vet. J. **70**: 559-61.

Higgins, D.A. (1966). Observations on the canine transmissible venereal tumour as seen in the Bahamas. Veterinary Record, **79**: 67-71.

Khan, L. A., Khante, G. S., Raut, B. M., Bodkhe, A. M., Chavan, M. S., Pagrut, N. S. and Bobde, S. P. (2009). Incidence of Venereal Granuloma and its Medicina -l treatment in stray dogs of Nagpur city. Veterinary World.**2 (1):** 13-14.

Kimeto, B. and Mugera, G.M. (1974). Transmissible venereal tumour of dog in Kenya. Bulletin of Animal Health and Production, **22**: 327-329.

O'Connor, J. J. (2005). Dollar's Veterinary Surgery. 4th edn. Pp. 754-756. CBS Publishers and Distributors.

Pandey, S.K., Dhawedkar, R.G. and Patel, M.R. (1977). Canine transmissible venereal sarcoma. Clinical trial with autogenous formalized vaccine. Indian Veterinary Journal, **54**: 852-853.

Richardson, R. C. (1981). Canine Transmissible Venereal Tumor. Comp contin Educ Prac Vet, **3**: 951-956.

Rogers, K. S. (1997). Transmissible Venereal Tumor. Comp contin Educ Prac Vet, **19 (9)**: 1036-1045.

Slatter, D. (2003). Text book of small animal surgery. 3rd edn. Saunders, an imprint of Elsevier Science (USA). Pp. 2437.

Stockmann, D., Ferrari, H.F., Andrade, A.L., Lopes, R.A., Cardoso, T.C. and Luvizotto, M.C.R. (2011). Canine Transmissible Venereal Tumors: Aspects Related to Programmed Cell Death. Braz J Vet Pathol, **4(1)**: 67-75.

Yang, T. J. (1988). Immunobiology of a spontaneously venereal sarcoma (Review). Anticancer Res, **8**: 9.

*****