SURGICAL MANAGEMENT OF INGUINAL HERNIA IN A MALE DOG

S. Ravikumar and L. Ranganath
Department of Surgery and Radiology, Veterinary College, KVAFSU, Bangalore-24.
[Received: 20.2.2014; Accepted: 05.6.2014]

Introduction

Inguinal hernias are protrusions of organs or tissues through the inguinal canal adjacent to the vaginal process. It may arise as a result of a congenital inguinal ring abnormality or may occur following trauma. The inguinal ring defect allows abdominal contents (e.g., intestine, bladder, uterus, omentem) to enter subcutaneous spaces (Bojrab *et al*., 1998). It can be unilateral or bilateral and frequently reported in females than males. Factors potentially involved in the development of inguinal hernias may be anatomical, hormonal, and/or metabolic in nature (Read and Bellenger 2003 and Smeak 1993). Clinical signs often reflect the size of the hernia and hernial contents and range from a painless inguinal mass to signs related to incarcerated or non viable intestine. Diagnosis of inguinal hernia might be accomplished by history, clinical signs, radiography and ultrasonography. In the present paper a rare case of inguinal hernia in a male dog and its successful surgical management is reported.

Case history and observations

A male non descript dog of 10 years old weighing about 25 kgs was presented with the complaint of huge swelling in the right side of the penis increasing since two months. On clinical examination the swelling was found extending from right inguinal region to the penis. Physical examination revealed no pain on palpation howeve, the contents of the swelling were reducible. Appetite, capillary refill time, heart rate, respiration rate and rectal temperature were within normal range. Haemoglobin and packed cell volume measured were within normal range. Based on history and clinical examination the case was diagnosed as inguinal hernia.

Surgical treatment

The patient was premedicated with 0.045 mg/kg Atropine sulphate, SC and 1 mg/kg diazepam, IV and was induced with 25 mg/kg thiopentone sodium IV given to effect. General anesthesia was maintained with isoflurane anaesthesia. The patient received an IV constant rate infusion of an isotonically balanced electrolyte solution at a rate of 10 mL/kg throughout the surgery. The patient was placed in dorsal recumbency, and the ventral abdomen was aseptically prepared in a standard fashion (Fig.1). An incision was made over inguinal swelling to allow exposure of hernial sac. Hernial sac contained omentum (Fig. 2). Adhesions between the omentum and hernial sac were separated. Contents were reduced back to the abdominal cavity. Hernial sac was excised at its neck. The hernial ring was closed with polyglactin 910 No. 1 size by simple interrupted pattern (Fig. 3). Care was taken to avoid the damage for external pudendal vessel and genitor femoral nerve. The subcutaneous tissue was sutured in a simple interrupted pattern using polyglactin 910 No. 0 to obliterate the dead space. Skin was closed by No. 0 polyamide suture in horizontal mattress pattern. Post operatively animal was administered with inj. Ceftriaxone Sodium (Intacef, Intas pharmaceuticals Ltd., Ahmedabad) at the dose rate of 20 mg/kg body weight IV for a period of 5 days. Meloxicam at the dose rate of 0.3 mg/kg body weight was administered daily once for three days SC.

Skin sutures were removed on 10th post-operative day.

Fig. 1: Showing swelling at the right inguinal region

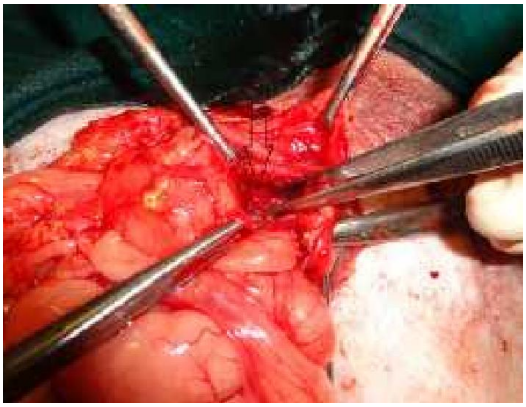

Fig. 2: Intraoperative photograph showing hernial contents and hernial ring

Fig. 3: Closing of internal inguinal ring

Result and discussion

Data from male dogs with inguinal hernia that have undergone herniorrhaphy are limited. Inguinal hernia has been classified as congenital and acquired (Waters *et al*., 1993). The dog in this report was 10 years old, and the history of hyperactivity like jumping and barking suggests an acquired cause of hernia. It seems that the protrusion of the omentum in right inguinal canal, concurrent with adhesions to the sac may be explained by the distinct role of the hyperactivity and harmonal influence worsening the hernias and development of clinical signs too. The risk for nonviable small intestine in dogs with longstanding inguinal hernia is relatively low (less than 5%). This could be because of small hernias go unnoticed until pain or vomition caused by mechanical or vascular obstruction of the intestine occur. Long standing hernias are more likely to be large and unnoticed. Large hernias are less likely to become incarcerated than small hernias. Experimental evidence suggests that sex hormones may influence the development of inguinal hernia in mice (Hazary and Gardener 1960). The role of trauma in the development of inguinal hernia remains unclear. The contribution of other factors, such as tensmus, vigorous physical activity, or obesity, has not been investigated. Inguinal hernias are reportedly rare in male dogs. Congenital inguinal hernia in dogs are more common in males than females (Waters *et al*., 1993). Due to the absence of incarceration and intestinal perforation or leakage in this reported case, the prognosis was evaluated to be good. Unilateral hernias are much

more common than bilateral hernias. Bilateral hernias seem to occur more frequently in young dogs. Despite the low prevalence of bilateral hernias, careful palpation of the contra lateral inguinal region for occult hernias is recommended. Surgical management of inguinal hernia consists of identification of the hernia sac, assessment of the viability of the hernia contents, surgical resection of nonviable tissue, herniorrhaphy, and, in some instances, neutering. Herniorrhaphy by simple interrupted or mattress sutures has been reported as effective (Parks, 1981). Omentum is reportedly the most common content present in canine inguinal hernia (Bojrab *et al*., 1998; Fossum *et al*., 2002; Grier *et al*., 1971; Waters *et al*., 1993). The omentum was also the main content of the right inguinal sac in this case too. The presence of the omentum may account for the asymptomatic nature and benign course of inguinal hernia in many dogs. However, the omentum may occasionally become incarcerated, resulting in clinical signs that include pain and depression (Waters *et al*., 1993). Small intestine viability is an important factor in determining whether herniorrhaphy is an elective or an emergency procedure. Complications in dogs treated surgically for inguinal hernia are incisional infection, wound dehiscence, hematoma, seroma, excessive postoperative swelling, hernia recurrence, sepsis or peritonitis and death. The reported case did not show any form of complications having been monitored for six months.

References

Bojrab, M.J., Ellison, G.W.,and Scolum, B. (1998) Current Techniques in Small Animal Surgery. 4th edn, Williams & Wilkins. pp. 552-554.

Fossum, T. W., Choyl, S, H., Donald, A, H., Ann, L, J., Howard, B, S. and Michael, D, W. (2002). Mosby Inc. missouri.. Small Animal Surgery. 2nd. edn. Mosby Elsevier. 261- 267.

Grier, R. L., Hoskins, J. D. and Wahlstrom. (1971). Inguinal hernia and Richter's hernia in a dog. J. Am. Vet. Med. Assoco **159**: 181-183.

Hazary, S. and Gardener, W.V., 1960. The influenee of sex harmones on abdomi nal musculature and the formation of inguinal and scrotal hernias in mice. *Anat. Rec.,* **136***:* 431

Parks, J. (1981). Herniation. In: Pathophysiology in Small Animal Surgery. (Bojrab MJ, ed.).

Philadelphia: Lea & Febiger. pp. 420-424. Read, R. A. and Bellenger, C. R. (2003) Hernias, In: SlatterD. ed. Textbook of Small Animal Surgery. Philadelphia: WB Saunders; pp. 446–470.

Smeak, D. A. (1993) Abdominal hernias, In: Bojrab M J. ed. Disease Mechanis -ms in Small Animal Surgery. Malver -n, PA: Lea & Febiger;, pp. 98–102.

Waters, D.J., Roy, R.G. and Stone, E.A. (1993). A retrospective study of inguinal hernia in 35 dogs. Vet. Surg., **22**(1): 44-49.

*****