BILATERAL HYGROMA IN A GREAT DANE DOG AND ITS SURGICAL MANAGEMENT

I. Nath, Jasmeet Singh, Sidhartha Sanker Behera, Prasant Kumar Sika and B.K Dwibedy

Department of Veterinary Surgery and Radiology, College of Veterinary Science and Animal Husbandry, Odisha University of Agriculture and Technology. Bhubaneswar-751003, Odisha.

[Received: 24.2.2014; Accepted: 07.6.2014]

A male Great Dane dog was presented with history of bilateral swelling over the elbow region since 2 months. Aspiration with sterile needle revealed it to be a case of hygroma and surgical treatment was planned accordingly with the hygroma over left limb to be operated firstly followed by other lesion after healing of first surgical wound. On 12th post-operative day, skin sutures were removed which revealed complete healing of the wound. A similar surgical procedure was carried out over the right elbow after 15 days of first surgery and the patient made an uneventful recovery.

Keywords: Hygroma, olecranon bursitis, surgical management.

Introduction

An elbow hygroma (elbow seroma, olecranon bursitis) is a fluid-filled cavity surrounded by dense fibrous connective tissue arising out of inflammation of an acquired subcutaneous bursa over the olecranon process of ulna (Fossum, 1997). The occurrence of this condition is commonly reported in horses but rarely in cattle (Venugopalan, 2004). It has been reported to occur most commonly in young dogs of large breeds before a protective callus forms over the bony prominence; however, they may occur in older animals with neuromuscular disease (Fossum, 2002). Repeated trauma to soft tissues overlying the bony prominence (olecranon process) causing subcutaneous accumulation of transudative fluid that eventually becomes encapsulated by fibrous tissue lined with a synovial membrane (Shappel and Little, 1992). Among the different dog breeds giant breeds like Irish wolfhound, Great Dane and Old English Mastiff appear to be particularly susceptible to this condition (White, 2003). The present communication puts on record a successful surgical management of bilateral elbow hygroma in a Great Dane dog and its surgical management.

Case History and Diagnosis

A nine months old male Great Dane dog was presented with history of bilateral round swelling over elbow region (Fig.1). It started as small sized swelling over both elbows and increased gradually to size of tennis ball over a period of 60 days. The consultant Vet aspirated it with a hypodermic needle to relive off swelling but it recurred again and it was referred for expert opinion and surgical treatment. Palpation of the mass revealed it to be soft and fluctuating with no evidence of pain. Clinical examination revealed normal rectal temperature (102.2^0F), heart rate (84 beats per minute) and respiratory rate (26 beats per minute). Aseptic aspiration revealed a transparent fluid thereby confirming it to be case of hygroma and surgical correction was planned accordingly.

Surgical Procedure

The animal was premedicated with atropine @ 0.04 mg/kg body wt. SC followed 10 minutes later by xylazine @ 1 mg/ kg IM respectively. General anaesthesia was induced by administration of ketamine @ 7.5 mg / kg body wt. IV and maintained by incremental doses of ketamine as and when needed during the surgical procedure. The dog was restrained in right lateral recumbency and aseptic

preparation over the left elbow region was done in routine manner. An elliptical incision was made along the posterolateral aspect of point of elbow and over the swelling. The bursa was gently separated from its soft tissue attachment by blunt dissection taking care not to rupture the bursa or injuring the joint capsule (Fig.2 and 3). The excess skin was trimmed off and the subcutaneous tissue was closed by simple continuous sutures using chromic catgut no.1 to obliterate the dead space followed by skin closure with horizontal mattress suture using braided silk no. 1 (Fig.4). The limb was bandaged properly from elbow region to paw region to restrict movement and prevent post operative swelling of the affected limb (Fig.5). Post-operatively broad antibiotic ceftriaxone @ 10 mg/ kg body weight for 5 days and analgesic meloxicam @ 0.2mg/ kg body weight for 3 days were administered intramuscularly. The wound was dressed on daily basis with povidone iodine solution and bandaged properly. The owner was advised to keep the animal with restricted movement to prevent wound dehiscence. Skin sutures were removed on 12th post-operative day and the wound healed completely without any complications.

A similar surgical procedure was carried out over the other limb after 15 days of first surgery (Fig.6) with similar post-operative treatment and management which led to uneventful recovery after 14 days of surgical procedure.

Fig.1. Bilateral hygroma at elbow region

Fig.2. After excision of the left mass

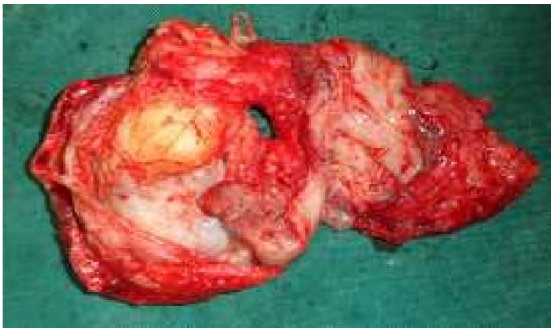

Fig.3. Excised bursa from the left side elbow

Fig.4. Closing of the wound

Fig.5. Bandaging of the limb

Fig.6. Surgical preparation of right one after healing of left

Results and Discussion

Olecranon bursitis is characterized by a movable swelling over the olecranon tuberosity and the fore limbs. A common cause of bursitis is direct trauma which leads to acute bursitis which swelling caused by bursitis can be of different size and can affect one or both fore limbs (Honnas *et al*., 1995; Fossum, 1997). The present clinical case was a bilateral condition affecting both appears suddenly while chronic bursitis occurs when the trauma is mild but repeated in nature (O'Connors, 2005). Chronic bursitis is characterized by accumulation of excessive bursal fluid, thickening of bursal wall, extrusions of fibrous bands or septa within the bursal cavity and generalized subcutaneous thickening (Fathy and Radad, 2006). The hygroma in present case was chronic in nature which might be due to constant irritation on the area of the olecranon owing to its heavy body weight.

Various treatment protocols have been formulated for management of bursitis in animal with the acute bursitis being treated by aspiration of the serous fluid and administration of hydrocortisone into the bursa to suppress inflammation. However, chronic bursitis can be treated by application of counter-irritants or incision of the bursa with application of an irritant to its interior lining. Aspiration of the contents and injection of an irritant like tincture iodine or 3-5% carbolic acid leads to destruction of the bursal lining followed by granulation, cicatrization and obliteration of the cavity (Venugopal, 2004).

Surgical treatment is considered to be an effective for treatment of olecranon bursitis particularly for the chronic proliferative and fibrous form (Fathy and Radad, 2006). Rapid and economic healing is also achieved by surgical intervention than conservative treatment (Arican *et al.,* 2005; Hayat *et al.,* 2009) and it has also been advocated when all other methods of treatment have failed and the bursa is large and composed of primarily fibrous tissue (Honnas *et al.,* 1995). In the present clinical situation, surgical correction was considered because of chronic nature of the lesion. Similarly, two step surgical procedure was planned because immobilization of both limbs simultaneously might create problem in normal movement of the patient which might increase the chances of wound dehiscence.

References

Arican, M., Kocabiyik, A. and Izci, C. (2005). Treatment of bilateral olecranon bursitis in a horse. *Indian Vet. J.,* **82**:325.

Fathy, A. and Radad, K. (2006). Surgical treatment and histopathology of different forms of olecranon and presternal bursitis in cattle and buffalo. *J. Vet. Sci*., **7**: 287-291.

Fossum, T. W. (1997). Small Animal Surgery. 2nd Edn. Mosby Publication. Missouri. pp 137-138.

Hayat, A., Cengiz Han, M., Sagliyan, A. and Biricik, H.S. (2009). Different treatment of olecranon bursitis in six horses. *J. Anim. Vet. Adv.,* **8**:1032-1034.

Honnas, C.M., Schumacher, J., McClure, S.R., Crabill, M.R., Carter, G.K., Schmitz, D.G. and Hoffman, A.G. (1995). Treatment of olecranon bursitis in horses: 10 cases (1986-1993). *J. Am. Vet. Med. Assoc.,* **206:** 1022-1026.

O' Connors, J.J. (2005). *Dollar's Veterinary Surgery.* 4th Edn., Tindal and Cox, London.

Shappel, K.K. and Little, C.B. (1992). Spec -ial surgical procedure for equine Skin, *In*: Equine Surgery. Auer, J.A. (Eds.),W. B. Saunders, Philadelphia. pp 272-284.

Venugopalan, A. (2004). *Essentials of Veterinary Surgery.* 4th Edn. Oxford & IBH Publishing. New Delhi.

White, R.A.S. (2003). Surgical treatment of specific skin disorders. *In:* Text Book of Small Animal Surgery. Slatter, D., (Ed). 3rd Edn. W.B. Saunders, Philadelphia, pp 339-355.