PERINEAL HERNIA AND ITS SURGICAL MANAGEMENT IN FIVE DOGS

Ajay Gupta[2], R. B. Kushwaha[1], Ankur Sharma[1], M. S. Bhadwal[3], D. K. Dwivedi[1] and P. Gupta[1]

[1]Assistant Professor, [2]Associate Professor, [3]Professor; Division of Veterinary Surgery and Radiology, FVSc&AH, SKUAST-J, R S Pura, Jammu – 181102 (J&K).

[Received: 25.8.2015; Accepted: 01.3.2016]

Perineal hernia is commonly observed in old intact male dogs, rare in female and uncommon in cats (Bellengerand Canfield, 2002). It occurs due to rupture of muscular pelvic diaphragm which supports the rectal wall. The herniated contents may be either pelvic organ or abdominal organ or occasionally both of them (Bellenger and Canfield, 2002). The cause of perinealhernia is still not clear but conditions like tenesmus secondary to prostatomegaly or chronic constipation or any condition that causesstraining such as urinary tract obstruction, colorectal obstruction, rectal deviation analsacculitis, cystitis and perianal inflammation may results in herniation (Krahwinkel, 1983; Bellenger and Canfield, 2002).The most consistent clinical sign is swelling in perineal region ventrolateral to the anus.Although, only twenty per cent cases treated medically shows symptomatic relief but recurrence is very common. Therefore, surgical intervention is the common procedure to cure the diseases. The present paper reports perineal hernia and its surgical management in five dogs.

Case history and Observations

Five intact male dogs were presented to Veterinary Referral Polyclinic, FVSC&AH, SKUAST-J, R S Pura-Jammu with the history of constipation, anorectal problem, dyschezia, dysuria (in 1 case) and ventrolateral swelling in the perineal region. Of the five dogs, three were German shepherd, and one each was Spitz and Non-Descript.

Tretment and Discussion

All the dogs were kept on laxative medicine Bisacodyl 5 mg orally at bed time a day before surgery and enema was given before herniorrhaphy. Perineal region was prepared for aseptic surgery and the animals were restrained in sternal recumbency with flexed hindlimbs and raised hindquarter. Anaesthesia was induced with atropine sulphate @ 0.04 mg/kg body weight I/M, xylazine hCl @ 2 mg/kg body weight I/M and ketamine hCl @ 10 mg/kg body weight I/M and maintained with ketamine and diazepam intravenously. The tail was pulled upward and tied and purse string suture was placed around the anus to preclude the contamination of surgical area. The surgical site was painted with Povidone-iodine 5% and a curvilinear incision was made over the swelling on one side of anus extending from ventro-lateral side of the base of the tail to the tuber ischii. The subcutaneous tissue and fascia was separated carefully. The hernial contents were retroperitoneal fat in two cases, rectal diverticulum in one case and intestine in two cases (Fig. 1).

The contents were manually reposed to their original position. The external anal sphincter muscle was sutured with levatorani muscle using No. 1 Polyglactin (Vicryl 910) suture material in simple interrupted pattern. Fascia and subcutaneous tissue were repaired in simple continuous pattern using catgut No. 1. Skin was sutured with Nylon in horizontal mattress pattern (Fig. 2). After completion of herniorrhaphy procedure, purse string suture was removed and area was painted with betadine solution.

Post-operatively, broad spectrum antibiotic ceftriaxone @ 20 mg/kg body weight I.V. five days, analgesic meloxicam @ 0.30 mg/kg body weight for three days, laxative bisacodyl 5 mg orally at bed time were administered, and antiseptic dressing of

surgical wound with Povidone-iodine 5% was done till suture removal. Four cases recovered without any complications; however, in one German shepherd dog, recurrence was reported probably due to weak muscle that could not hold the suture,

Fig. 1: Herniated small intestine in a Spitz dog of bilateral perineal hernia.

Fig. 2: German Shepherd dog immediately after repair.

straining during defecation and rectal diverticulum. The dog was reoperated successfully by anchoring the external wall of rectum with surrounding structure.

German shepherd dogs are more prone to anorectal problems like fistula, fissure, anal saculitis and diverticulum due to deeply located anal gland as also reported by Aronson (2002). Causing higher percent of perineal hernia in this breed. The ages of dogs were 5 years in Spitz, 6, 7 and 12 years in GSD and 9 years in ND with an average age of 7.8 years. Earlier studies have also shown that the disease occurs in middle aged to older dogs due to higher level of testosterone that might have resulted in hypertrophy of prostate gland and ultimately perineal hernia as also recorded by Hedlund (1997) and Bellenger and Canfield (2002).

Female dogs are rarely affected due to greater strength, size and area of rectal attachments of levatorani muscles as well as absence of prostate gland. In present study, none of female dog was affected. However, it may occur due to trauma as also mentioned by Hedlund (1997). The swelling in perineal region was seen for the last one month in 2 cases, between 1-2 month in 2 cases and about 2 years in one case. The wide variation in the presentation of case to the clinics was probably due to unawareness of condition, area hidden by the tail and stoppage of feces occurs progressively. The contents were reducible in four cases and irreducible in one German shepherd dog which had rectal diverticulum. Perineal swelling was unilateral in three cases; of which two at right side and one at left side (Fig. 3) and bilateral in two cases (Fig. 4). Niles and Williams (2008) have also reported unilateral and right side perineal hernia is more common than the bilateral and left side.

The most commonly herniated contents are retroperitoneal fat, fluid, rectum, prostate, paraprostatic cyst, jejunum, colon, urinary bladder or connective tissue as also reported by Maute *et al.,* (2003) and Malik *et al.,* (2007). In three cases, contents herniated through between external anal sphincter and levatorani muscle whereas, in remaining two cases, ruptured area could not be ascertained.

Bellenger and Canfield (2002) have also reported similar finding. Castration was done in three dogs following herniorrhaphy to eliminate the potential hormonal influence causing perineal herniation. This is particularly important when the prostate was increased in size and its enlargement would cause straining and unneeded stress on the

surgical repair as also mentioned by Maute *et al.,* (2003).

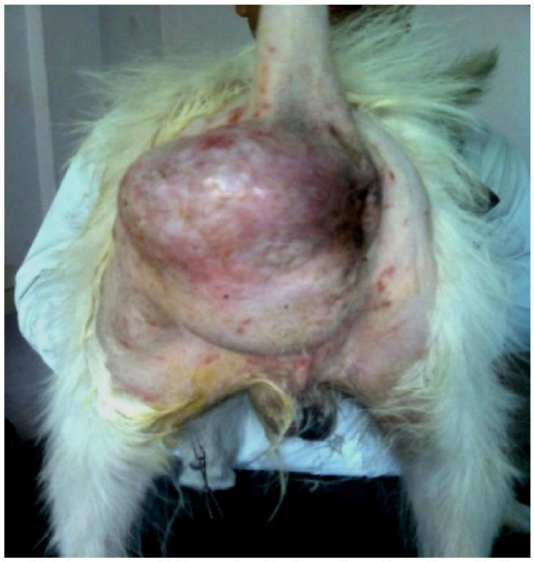

Fig. 3: A 5 years old male Spitz dog having left side perineal hernia.

Fig. 4: A 9 years old male German Shepherd dog having bilateral hernia. Note the symmetrical swelling and caudal projection of anus.

References

Aronson, L. (2002). Rectum and Anus. In: Textbook of Small Animal Surgery, 3rdedn. Eds Slatter, D. Philadelphia, W.B. Saunders Co. Pp. 682-708.

Bellenger, C.R. and Canfield, R.B. (2002). Perineal hernia. In: Textbook of Small Animal Surgery, 3rdedn. Eds Slatter, D. Philadelphia, W.B. Saunders Co. Pp. 487–498.

Hedlund, C.S. (1997). Surgery of perineum, Rectum, and Anus. In: Small Animal Surgery. 1stedn.,Fossum T.W., ed. Missouri: Mosby Inc. Pp. 352-356.

Krahwinkel, D.J. (1983). Rectal diseases and their role in perineal hernia. *Vet. Surg.;* **12:** 160–165.

Malik, V., Pandey, R.P. and Singh, B. (2007). Perineal herniorrhaphy with cystopexy in male dogs. *Indian J. Vet. Surg.*; **28**(2): 128.

Maute, A.M., Koch, D.A. and Montavon, P.M. (2003). Perineal hernia in dogs-colopexy, vasopexy, cystopexy and castration as an alternative therapy in 32 dogs. *EJCAP.*; **13:** 104-109.

Niles, J.D. and Williams, J.M. (2008). Perineal hernia with bladder retroflexion in a female cocker spaniel. *Journal of Small Anim. Practice;* **40:** 292-94.