SURGICAL MANAGEMENT OF GASTRIC FOREIGN BODY (PLASTIC CUBE) IN A DOG

S. Ravikumar, B.N. Nagaraja, L. Ranganath and C. Sachin
Department of Surgery and Radiology, Veterinary College, KVAFSU, Bangalore-560 024.
[Received: 17.7.2015; Accepted: 10.2.2016]

Ingestion of foreign bodies is relatively common in dogs. A year old female Great Dane dog was presented with the history of vomition since a week which was not responded for medical treatment. On observation, animal was dull and dehydrated. On abdominal palpation a hard mass was palpable in cranial abdomen within the ribcage. Lateral abdominal survey radiography was normal but six hour barium gastrogram reveals stasis of barium in stomach suggestive of gastric foreign body. Upon exploratory laparogastrotomy plastic cube was found as a gastric foreign body. Postoperatively animal made an uneventful recovery.
Key words: Plastic cube, Gastrogram, Foreign body, Dog.

Gastrointestinal foreign bodies are commonly encountered in companion animal practice and may present with a variety of clinical signs depending on the location, the degree and the duration of the obstruction (Aronson and Brockman, 2000). Gastric foreign bodies usually cause vomition because of outflow obstruction, gastric distention, and/or mucosal irritation. Occasionally, however, gastric foreign bodies are asymptomatic, incidental findings on abdominal radiographs. Radiopaque foreign bodies may be diagnosed with survey radiographs, but many foreign bodies are radiolucent. A positive contrast gastrogram or double-contrast gastrogram can be utilized to delineate radiolucent foreign bodies, Double contrast studies using both air and a positive contrast agent (i.e., barium sulfate) are more sensitive than positive contrast procedures, gastric foreign bodies can be removed through a gastrotomy (Fossum, 2013). The present paper reporting successful surgical management of radiolucent foreign body from stomach.

Case history and Observations

A year old female intact Great Dane dog weighing about 40 kgs was presented to the Department of Surgery and Radiology, Veterinary College, KVAFSU, Bangalore with the history of vomition since a week which was not responded for medical treatment. On clinical examination animal was dull and dehydrated. Physiological parameters were within the normal range and laboratory parameters were normal except haemoconcentration. Abdominal palpation revealed a hard mass in cranial abdomen within the rib cage. Survey radiography of lateral abdomen does not revealed any radiodense foreign body but six hour barium gastrogram revealed stasis of barium in the stomach suggestive of gastric foreign body (Fig.1). With the above clinical support, it was confirmed as gastric foreign body and further it was planned for exploratory laparogastrotomy.

Treatment and Discussion

The dog was sedated using 0.5 mg/Kg BW Diazepam and 0.1 mg/Kg BW of Butorphanol intravenously. The induction was achieved using propofol at 4 mg/Kg BW IV followed by mixture of Isoflurane and oxygen for maintenance. Animal was restrained in dorsal recumbency. Cranial midline skin incision was made from the xephoid to umbilicus. Abdominal contents were inspected and a hard mass was palpated in the stomach. Stomach was isolated and exteriorized from rest of the abdominal contents with moistened laparotomy sponges. Stay sutures were placed to reduce the contamination placed to reduce the contamination placed to reduce the contamination while manipulation of the stomach. Gastric incision was made at hypovascular area of the ventral aspect of the stomach between greater and lesser curvature. Gastric foreign body was removed out of the stomach using Allis forceps (Fig.2) and it was

found to be a plastic cube (Fig.3). Stomach was closed with 3-0 polyglactin 910 suture material in a two-layer inverting seromuscular pattern (Cushing followed by Lembert pattern). Entire intestinal tract was examined for additional foreign bodies and abdominal cavity was lavaged with warm saline.

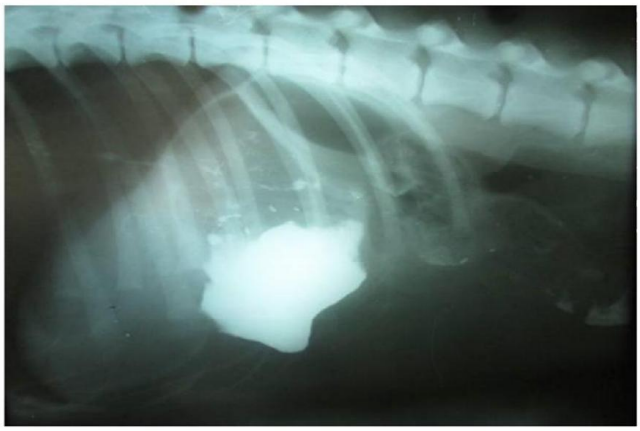

Figure 1. Six hour barium gastrogram showing stasis of barium in stomach.

Figure 2. Intraoperative photograph showing foreign body removal from the stomach

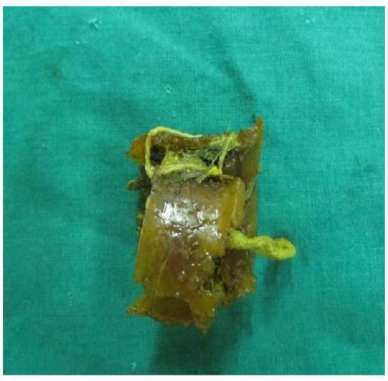

Figure 3. Gastric foreign body (plastic cube) after removal from the stomach

Linea alba was closed with simple interrupted pattern using no. 1 polyglactin 910. Subcutaneous tissue and skin were closed routinely. Animal recovered from anesthesia without any complications. Postoperatively animal was given ceftrioxone @ 20 mg/kg BW, IV twice daily for five days, Pentazocine @ 1mg/kg BW for three days. Intravenous fluids were given for 48 hours during this period animal did not show any signs of vomition. Animal was given liquid food 48 hours postoperatively for three days and later regular food. Animal made fruitful recovery and skin sutures were removed on 10th post operative day.

Dogs are indiscriminate eaters and often ingest rocks, plastic toys, cooking bags, and other objects. Capak *et al.* (2001) reported that the usual location of the canine gastro intestinal foreign bodies was recorded at stomach and ilio-caecal junction and the mean duration of clinical signs at presentation was six days; similarly, in the present case, the foreign body was found at stomach and a week duration of clinical signs. The survival rate for the treatment of gastric foreign bodies in dogs was 94 per cent and higher survival rate was reported in young dogs and the dogs less than two years of the age as also mentioned by Capak *et al.* (2001).

Abdominal survey radiographs were unremarkable in many GI foreign body cases *viz.* stones, metals, bones etc. Abdominal ultrasonography can be useful in the diagnostic evaluation of many disorders that cause vomition, including gastrointestinal foreign bodies as also reported by Fazio (2006). The ceftrioxone was used as post operative antibiotic; as intravenous, broad spectrum cephalosporins are recommended for gastrointestinal surgeries by Papazoglou *et al.* (2003) also. In the present case also, upper abdominal survey radiograph was used as primary diagnosing modality followed by upper GI contrast study for confirmation. Timely diagnosis, strict intraoperative asepsis and intensive postoperative management may have reduced patient mortality.

References

Aronson, L.R. and Brockman, D.J.C. (2000). Gastrointestinal emergencies. *V. Clin. North Am. Small Anim. Pract.;* **30:** 555-579.

Capak, D., Brkic, A., Harapin, I., Maticic, D. and Radisic, B. (2001). Treatment of the foreign body induced occlusive ileus in dogs. *Veterinarsiki Archiv.*; **71:** 345- 359.

Fazio, K.A. (2006). Diagnosing GI foreign bodies. *Banfield;* 2 (6): 24-32.

Fossum, T.W. (2013). Gastric foreign bodies. *In:* Small Animal Surgery. 4th edn. Mosby, Elsevier. Pp. 479-481.

Papazoglou, L.G., Patsikas, M.N. and Rallis, T. (2003). Intestinal foreign bodies in dogs and cats. *Compend. of Con. Edu. for the Prac. Vet.;* **25**: 830-843.