SURGICAL MANAGEMENT OF URINARY BLADDER LEIOMYOSARCOMA IN A DOG

D.R. Manjunatha, M.C. Anilkumar, N. Nagaraju, B.C. Girish, Balappanavar Basavaraj and M.S. Vasanth

Department of Teaching Veterinary Clinical Complex, Veterinary College, Gokula, Vidyanagar Post, Hassan - 573 202 (Karnataka).

[Received: 31.7.2015; Accepted: 01.2.2016]

An 11year old non-descript male dog with a circular mass On abdominal palpation was brought to our TVCC.. Haematological and biochemical investigation revealed leucocytosis with neutrophilia, reduced hemoglobin, marginal elevated creatinine and blood urea nitrogen levels with normal alanine-amino tranferese. Urine analysis revealed erythrocytes in urine with increased specific gravity. Hyperechoic pedunculated mass measuring about 2.3cm X 2.3cm in the lumen of the urinary bladder was observed on ultrasonographic examination of the abdomen. Cystotomy revealed pedunculated growth on dorsal surface of the urinary bladder and the growth was excised. Histopathological examination confirmed leiomyosarcoma of urinary bladder. The dog made uneventful recovery on 10th postoperative day.

Key words: Hematuria, Cystotomy, Leiomyosarcoma.

Urinary bladder tumors account to 1.5-2.0 % of all reported canine tumors (Saltter, 2002). The most common type of urinary bladder cancer is transitional cell carcinoma (TCC), other less common types of tumors of the bladder may include leiomyosarcomas, fibrosarcomas and other soft tissue tumors. Smooth muscle origin neoplasia of the urinary bladder wall is rare in dogs. Leiomyosarcoma and leiomyoma are the common mesenchymal tumors of the urinary bladder in cats and dogs which account upto12% of all primary urinary bladder tumors (Heng *et al.*, 2006). Leiomyosarcoma and leiomyoma are usually small and located in the trigone or neck of the urinary bladder and these are locally aggressive and infrequently metastasize to regional lymph nodes, liver, pancreas, kidneys, intestines, omentum, diaphragm, heart and lungs (Seely *et al.*, 1978). A rare case of leiomyosarcoma in the urinary bladder of male dog and its surgical management is hereby reported.

Case history and Observation

A11 year old non-descript male dog was presented to of Department of Teaching Veterinary Clinical Complex, Veterinary College, Hassan, with a history of decreased appetite, vomition, dysuria, with frequent attempts to urinate and hematuria since one week. The dog was treated by local veterinarian with H_2 blockers, anti-emetics and a course of antibiotics (Streptopenicillin), there was no improvement and hematuria still persisted. So the case was referred to Veterinary College Hospital, Hassan for further investigation. Clinical examination of the dog revealed normal temperature, heart rate, respiration rate and slightly congested mucous membrane. Upon abdominal palpation an enlarged mass was palpable in the pelvic region. Hematological and biochemical analysis revealed leucocytosis (28,000/cumm), decreased haemoglobin (8 gm%), normal serum glutamic pyruvic treansaminase level and increased creatinine (2.2 mg/dl) and blood urea nitrogen levels (35 mg/dl). Urine analysis revealed erythrocytes in urine with increased specific gravity. Hyperechoic pedunculated mass measuring about 2.3cm X 2.3cm in the lumen of the urinary bladder was observed on ultrasonographic examination (Plate-1). Based on the abdominal palpation and ultrasonographic examination, the case was diagnosed as tumor in the urinary bladder.

Treatment and Discussion

The pet was given pre-anaesthetic with atropine sulphate @ 0.04 mg/kg b.wt i/m. and xylazine hydrochloride @ 1.0 mg/kg b.wt i/m. Then the general anesthesia was induced with thiopentone sodium @12.5

mg/kg b.wt i/v and maintained with Isoflurane. On indirect midline incision cystotomy was done. The urinary bladder was exposed and a round lollipop sized mass was seen hanging near the neck of urinary bladder (Plate-2). The wall of the urinary bladder was thickened. Tumor mass was excised (Plate-3) and sent to the Deptt. of Pathology for histopathology. The neoplastic proliferated spindle shaped cells were seen intervening as bundles. Occassional mitotic figures and presence of inflammatory cells below the transitional epithelium. High degrees of anaplastic changes were also seen. As such the mass was arising from smooth muscle cells of the urinary bladder, confirmed Leiomysarcoma (Plate-4).

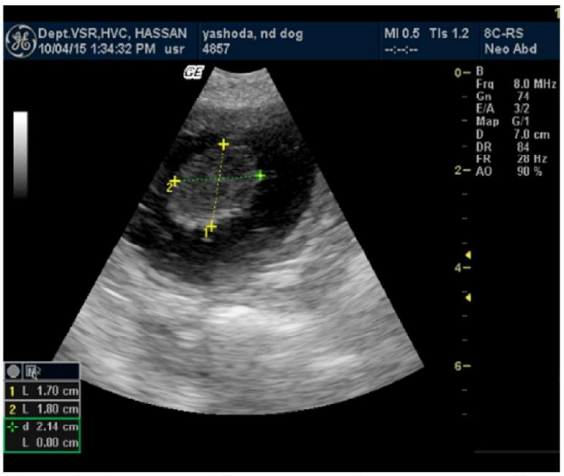

Plate-1: Ultrasound image showing hyperechoic mass within the urinary bladder.

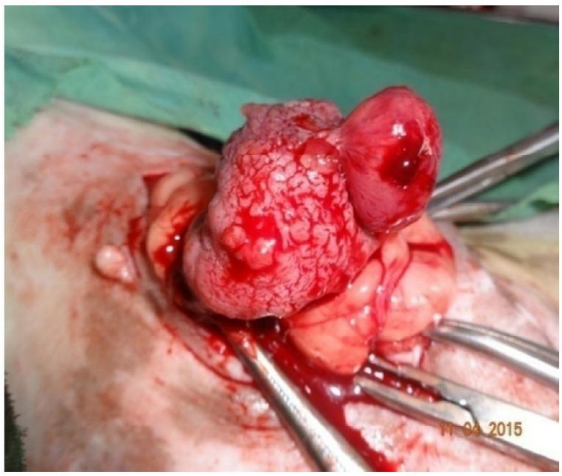

Plate-2: Pedunculated mass hanging from the dorsal surface of urinary bladder.

Plate-3: Tumor mass after excision

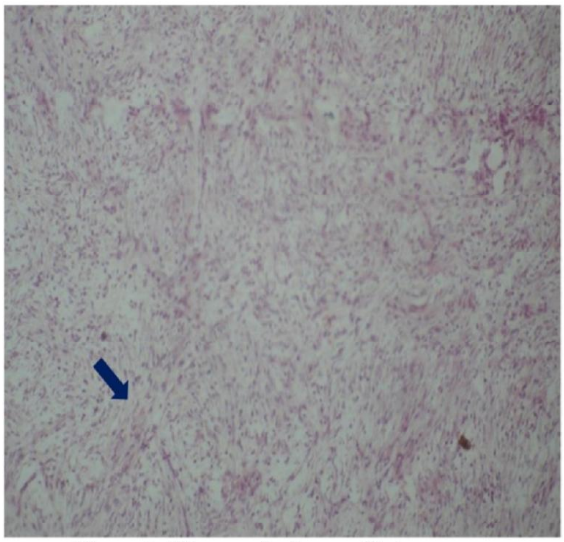

Plate-4: Histopathology of leiomyosarcoma (Neoplastic cells intervening as bundles, short arrow)

The tumor mass was removed from the urinary bladder which was around 2 cm in diameter and surgical wound was sutured by standard procedure. Post operatively the animal was given 5% DNS fluid intravenously, 500 ml along with a Ceftriaxzone @ 25 mg/kg b.wt intravenous for 5 days and meloxicam and B-complex injections for 5 days. The pet started taking food and water by 3rd day itself. The skin sutures were removed after 10 days. After 3 month again ultrasound scanning of urinary bladder was performed which did not reveal any re-growth of tumour in the urinary bladder. In the present case the pet showed improvement immediately because there was

no metastasis of the tumor to other pharanchymatous organs.

Neoplasms of the canine and feline urinary bladder are diagnostic and therapeutic challenges to the veterinary clinician. The diagnosis of a urinary bladder neoplasm is generally delayed because of a lack of overt clinical signs or a partial response to empirical treatment. Surgical resection is the treatment of choice. The prognosis of dogs and cats with urinary bladder neoplasms is based on tumour type, location, depth of bladder wall invasion, and presence of regional or distant metastasesas also reported by Schwarz and Willer (1989), where as in present case diagnosis was made based on the clinical examination and ultrasonographic scanning.

Leiomyosarcoma is a rare malignant tumour, found especially in hollow organs like uterus, vagina, intestine, stomach, urinary bladder and esophagus as also recorded by Sastry and Rama Rao (2001). In present paper leiomyosarcoma was reported in urinary bladder. Compared to cancer of other locations of the body, urinary bladder cancer is unusual, comprising approximately 2% of all cancers in the dogs and the most common cancer of the dog urinary bladder is invasive transitional cell carcinoma of intermediate to high grade and smooth muscle neoplasia like liomyoma and leiomyosarcoma were rare in canines as also reported by Heng *et al.,* (2006) and Slatter (2002). A rare case of leiomyosarcoma in dogs has also been reported in this study.

Seely *et al.*, (1978) reported that leiomyosarcoma in the neck of the urinary bladder of dog, as the cancer enlarges in the bladder, can cause obstruction to the flow of urine from the kidney to the bladder or from the bladder to the outside of the body; and leiomysosarcoma is likely to metastasise to lymph nodes and other organs like liver, lung, spleen etc., contrary to this, in the present case the signs like attempts to make frequent urination, pain at the time of urination and hematuria were mainly due to only ulceration of tumour, as radiographic and ultrasonographic study did not reveal any kind of metastasis.

Conclusion

A successful diagnosis and surgical management of a rare case of leiomyosarcoma in the urinary bladder of male dog was reported.

References

Heng, H.G., Lowry, J.E., Boston, S., Gabel, C., Ehrhart, N. and Gulden, S.M. (2006). Smooth muscle neoplasia of the urinary bladder wall in three dogs. *Vet. Radiol. Ultrasound;* **47**(1): 83-86.

Sastry, G. A. and Rama Rao, P. (2001). Neoplasams. In. Veterinary Pathology. 7th edn. CBS, New Delhi. Pp. 232.

Schwarz, P.D. and Willer, R.L. (1989). Urinary bladder neoplasia in the dog and cat. *Probl.Vet. Med.*; **1**(1): 128-140.

Seely J.C., Cosenza, S.F. and Montgomery, C.A. (1978). Leiomyosarcoma of the canine urinary bladder, with metastases. *J. Am. Vet. Med. Assoc.*; **172**(12): 1427-1429.

Slatter, D. (2002). Oncology: Urinary system. In: Small Animal Surgery. 3rdedn. Saunder, Elsevier. Pp. 2451-2459.