MAMMARY GLAND TUMORS IN DOGS - A REPORT OF TEN CASES

Ankur Sharma[1], R.B. Kushwaha[1], Ajay Gupta[2], M.S. Bhadwal[3], P. Gupta[1] and D.K. Dwivedi[1]
[1] Assistant Professor, [2] Associate Professor, [3] Professor, Division of Veterinary Surgery and Radiology;
FVSc & AH, SKUAST-J, R S Pura, Jammu - 181102 (J&K).
[Received: 25.8.2015; Accepted: 29.2.2016]

Mammary gland cancer is the second most common neoplasia in canines which appears in senile bitches above 10 years of age is about 52% (Moulton, 1999; Srivastava *et al.*, 2009[2]); of which 40-50% are malignant (Srivastava *et al.*, 2009[1]). Mammary tumors of female dogs have greatly increased in the recent years, thus demanding rapid diagnosis and effective treatment in order to determine the animal survival (Andrade *et al.,* 2010). The last pair of mammary glands were most frequently affected with multiple tumors in dogs (Shekhar *et al.,* 2001). It is well documented that ovariohysterectomy significantly decreases the risk of development of mammary gland tumors in later life (Cronin, 2010). Although there are several ways to manage the condition, but surgical removal of affected gland is the most successful. The present paper describes the report of ten female dogs suffered with mammary gland tumour.

Case history and Observations

Ten female dogs were presented to the Teaching Veterinary Clinical Complex, FVSc & AH; SKUAST-J, R S Pura of Jammu with the history of growth in the mammary glands for variable periods of time. Breed, age, duration of growth, nature and location of growth and physiological parameters were recorded in each case. Breed wise distribution of mammary gland tumor revealed that Spitz (5) were commonly affected breed followed by German shepherd (3), Doberman (1) and Dalmation (1). The common age for mammary tumor affection was between 10-12 yrs (50%), 8-10 years (20%), 6-8 years (20%) and 4-6 years (10%).

Among the affected mammary gland, inguinal mammary glands (left-5, right-1) were most commonly affected (Fig. 1), followed by cranial abdominal (3) and caudal abdominal (1). In most cases, only one gland was grossly affected. It has been observed that the last pair of mammary glands was most frequently affected with multiple tumors due to a large volume of mammary tissue present in them.

Fig. 1: A large, solid, single tumour involving right inguinal gland and another small solid tumor involving right abdominal gland.

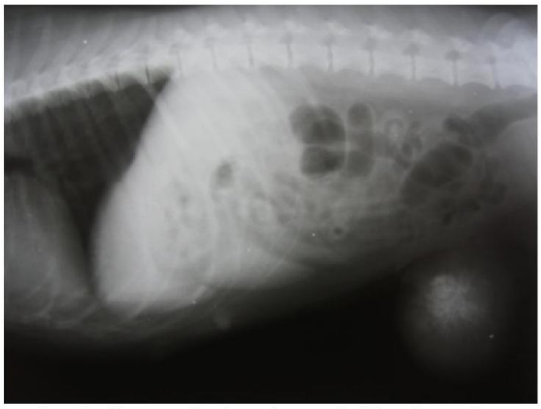

Fig. 2: Radiograph showing calcification of inguinal gland and metastasis in lung.

The natures of growth were hot and solid (9) Vs cystic (1), single mass (3) Vs multilobulated (7) and intact (7) Vs ulcerated (3). Duration of growth varied from 1 month

to 2 years, probably due to delay in presentation to the clinics by the owner. Previous medicinal treatment had been given in two cases by a veterinarian without any response.

Radiographs of two bitches showed calcification of the mammary gland and lung metastasis (Fig 2).

Treatment and Discussion

The growths were removed by a routine surgical procedure. All the mammary growths were excised surgically under Atropine sulphate 0.04 mg/kg b.wt. i/m and Xylazine Hcl 2 mg/kg b.wt. i/m premedication and Ketamine Hcl 10 mg/kg b.wt. i/m dissociative anaesthesia. Intraoperative anaesthesia was maintained by a combination of Ketamine Hcl and Inj Diazepam intravenously. Post-operative treatment included antibiotic therapy with Inj. Ceftriaxone i/m for 5 days; Inj. Meloxicam @ 0.3 mg/kg b.wt. i/m for 3 days and daily dressing of the surgical wound was done with Betadine solution 5% till suture removal. All the cases showed complete recovery without any complications except in one case where severe haematoma was noticed.

In pertext to our observation as cited above, the earlier researchers have also reported a high incidence of mammary glands tumor in German Shepherd (Ravikumar *et al.*, 1999; Maiti, 2004), Samoyed or white spitz (Sharma, 2004) and Doberman (Raghatwan, 2006). Mulligan (1975) reported 90 percent of the mammary tumor cases occur between the age group of 8-15 years. However, Brodey *et al.* (1983) reported peak incidence at the average age of 10 years. Owen (1979) observed marked increase in incidence of mammary gland tumor with increasing age; however the incidence of tumor declined after 11 years. The higher incidence of mammary gland tumour in female dogs are due to increased level of estrogen in older age groups but still the exact relationship between age and the development of mammary neoplasia could not be established.

In our study, it was observed that lateral thoracic radiographs were sufficient to detect pulmonary metastasis in dogs; contrary to this other researchers have recommended a ventro-dorsal view and two opposing lateral chest radiographs for detecting metastasis of lungs due to mammary tumor in dogs (Thrall, 1994).

Classical modalities of cancer therapy include surgery, radiation and chemotherapy. cryosurgery, immunotherapy, hyperthermia and use of biologic response modifiers are few among the new modalities. Chemotherapy yields best results when used to treat rapidly growing tumors as also reported by Sharma *et al.,* (2010). Medical treatment other than chemotherapy is of no avail and surgery remains the mainstay treatment for mammary tumor in dogs regardless of prognosis as also mentioned by Morrison and Hahn, (2000). It is always recommended that the removal of entire chain of mammary tissue in which the tumor or tumors were found as also reported by Bojrab (1975) and Srivastava *et al.*, (2009)[3]. . Bilateral mastectomy was not recommended since the amount of trauma inflicted was great and wound healing may present monumental problems. More radical procedures like stage bilateral or regional mastectomy should be followed in healthy and young patients whereas conservative procedures like local mastectomy/ lumpectomy are advised in debilitated patients as also reported by Ferguson, (1985). We have observed that adjuvant chemotherapy administered along with surgery gave more effective success rate than surgical excision alone.

References

Andrade, F.H.E., Figueiroa, F.C., Bersano, P. R.O., Bissacot, D.Z. and Rocha, N.S. (2010). Malignant mammary tumor in female dogs: environmental contaminants. *Diagnostic Pathology*; **5**: 45.

Bojrab, M. J. (1975). Current Techniques in Small Animal Surgery. 2nd Ed. Lea and Febiger, Philadelphia. Pp. 269-272.

Brodey, R.S., Goldschmidt, M.H. and Roszel, J.R. (1983) Canine Mammary Gland Neoplasms. *J. Am. Anim. Hosp. Assoc.*; **19** (1): 61-90.

Cronin, K.L. (2010). Current recommendations for mammary gland

tumors in dogs. *In:* http://veterinarynews.dvm360.com

Ferguson, H.R. (1985). Canine Mammary gland tumors. *Vet. Clin. North. Am. Small Anim. Pract.*; **15**: 501-11.

Maiti, S.K. (2004). Mammary tumors in canine – Analysis of 33 cases. *Indian J. Vet. Surg.*; **25**(2): 128.

Morrison, W.B. and Hahn, K.A. (2000). Mammary Gland Tumors – Dogs. In: The 5- Minute Veterinary Consult II Ed. (Ed. Dan Limmer) Lippincott Williams and Wilkins, Philadelphia. Pp. 934-935.

Moulton J.E. (1999). Tumors in Domestic Animals, 3rd Edition. Berkley, University of California Press. Pp. 518-543.

Mulligan, R.M. (1975). Mammary Cancer in the dog: A Study of 120 cases. *Am. J. Vet. Res.;* **36**: 1391-96.

Owen, L.N. (1979). A comparative study of canine and human breast cancer. *Invest Cell Pathology,* **2**(4): 257-75.

Raghatwan, Y.S. (2006). A study on mammary tumor in canines. M.V.Sc. thesis submitted to Maharashtra Animal and Fishery Sciences University, Nagpur.

Ravikumar, K.P., Vasanth, M.S., Ranganath, B.N. and Jayadevappa, S.M. (1999). Incidence of Mammary Tumor in canines. *Ind. Vet. J.*; **20**: 115.

Sharma, H.K. (2004) Studies on presurgical use of mitomycin and vinblastine in canine mammary neoplasm, M.V.Sc. thesis, Punjab Agricultural University, Ludhiana.

Sharma, A., Dhakate, M.S. and Upadhye, S.V. (2010). Chemotheraputic Management of Canine Mammary Tumors. *Vet. Scan*; **5** (1): 55.

Shekhar, C.S., Vijayasarathi, S.K., Gowda, R.N.S., Vasanth, M.S. and Rao, S. (2001). An epidemiological study on canine mammary tumors. *Indian Vet. J.*; **78**: 107-109.

Srivastava, A.K., Sharma, A.K. and Singh, Bharat, (2009)[1]. Canine Mammary Tumours: A Study on Occurrence and Distribution Pattern. *Indian J. Vet. Path.*; **33** (1): 109-111.

Srivastava, A.K., Singh, Bharat, Srivastava, A.K., Sinha, Neeraj and Sharma, A.K., (2009)[2]. Canine Neoplasms: A Study on Occurrence and Distribution Pattern. *Indian J. Vet. Surg.*; **30**(1): 45-46.

Srivastava, A.K., Singh, Bharat, Srivastava, A.K., Lal, H.P., Sinha, Neeraj and Sharma, A.K., (2009)[3]. A Study on Chemo-Surgical Managements of Mammary Tumours in Dogs. *Indian J. Vet. Surg.*; **30**(1): 27-30.

Thrall, D.E. (1994) Textbook of Veterinary Diagnostics Radiology, 2nd edn., W.B. Saunders, Philadelphia. Pp. 388-414.