SERTOLI CELL TUMOUR IN A CRYPTORCHID BLACK MINIATURE DACHSHUND – A CASE REPORT

Indramani Nath[1], Biswadeep Jena[2] and Sidhartha Sankar Behera[2]
[1]Professor; [2]Assistant Professor, Department of Veterinary Surgery & Radiology, College of Veterinary Science & Animal Husbandry, Orissa University of Agriculture and Technology, Bhubaneswar – 751 003, Odisha.
[Received: 28.9.2015; Accepted: 04.4.2016]

A 7.5 year old black Miniature Dachshund dog was presented with a firm, nodular, abnormally enlarged left cryptorchid testis. After being removed surgically, histopathology of the representative tissue sample corroborated it to be a Sertoli cell tumor (SCT). Obligation of proper surgical techniques and maintenance of adequate postoperative measures rewarded with uneventful recovery of the animal.
Key words: Canine, Dachshund, Cryptorchid, Sertoli cell tumour.

Cryptorchidism, the most common congenital testicular defect, is a failure of one or both testes to descend into the scrotum at the usual time (Boothe, 2003). Testicular neoplasia is the second most common tumor types in male dogs. Neoplasia of the testis occurs in approximately one percent of entire male dogs and comprises of 91% of male genital system. According to the latest World Health Organization (WHO) classification of tumours of domestic animals, Sertoli cell tumor (SCT) is one of the most common types of testicular tumour reported in dogs (Grieco *et al.*, 2008; Navya *et al.*, 2013). The present communication deals with the successful surgical management of SCT of a cryptorchid testis in a black Miniature Dachshund.

Case History and Observations

A 7.5 year old black Miniature Dachshund dog, weighing around 5 kg, was presented to the department of Veterinary Surgery & Radiology, College of Veterinary Science & Animal Husbandry, Orissa University of Agriculture and Technology, Bhubaneswar, Odisha with a potato shaped, firm and nodular mass at the left posterior inguinal region. Anamnesis affirmed plodding enlargement of the mass since last 3 months. The enlargement had begun to interfere with the movement and daily life style of the animal. Discreet physical examination revealed that the animal was bilaterally cryptorchid and the left undescended testis had befallen into an abnormal tumorous mass. Conversely, the contralateral testis had atrophied (Fig. 1). Beside above findings, animal was showing alopecia, rough and brittle hair coat. Hence it was recommended to ablate the undescended enlarged testis.

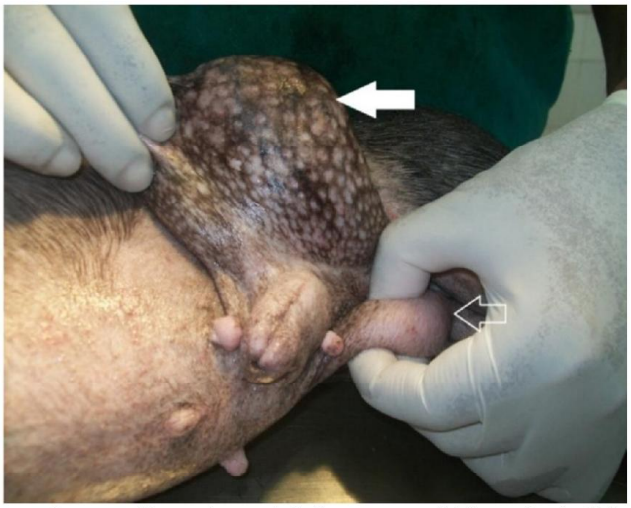

Fig.1. Showing firm, nodular, abnormally enlarged left cryptorchid testis (solid arrow) and atrophied right cryptorchid testis (hollow arrow) in the posterior inguinal region of the Black Miniature Dachshund dog

Treatment and Discussion

The animal, presented after overnight fasting, was pre-anaesthetised with a atropine sulphate at the dose rate of 0.04 mg/kg body weight and xylazine hydrocholride at the dose rate of 1.0 mg/kg body weight administered intramuscularly to achieve sedation. After achievement of adequate sedation and smooth muscle relaxation, general anaesthesia was induced and maintained with ketamine hydrochloride at the dose rate of 5.0 mg/kg body weight intravenously. The cephalic vein was catheterized and saline-dextrose solution was administered at 10 mL/kg/hr perioperatively. After aseptic preparation of left posterior paramedian region, a circular skin incision was given around the mass and the underlying subcutaneous tissue, spermatic fascia were incised over the testis to expose the parietal vaginal tunic. The testicular mass and spermatic cord were exteriorized and freed from their scrotal attachment by reflecting the spermatic fascia with a gauze sponge. Components of spermatic cord and tunics were doubly ligated by transfixation ligation. The spermatic cord was transected distal to the ligature and returned to the inguinal region. Abdominal incision was closed routinely.

Post-operative care consisted of parenteral administration of ceftriaxone + tazobactam at 10 mg/kg body weight and Meloxicam at 0.1 mg/kg body weight for 5 days. The patient recovered well without any lasting effects and complications from its surgery.

The weight of the excised testicular mass was 185 gram. Grossly the testicular mass was quite firm, nodular and enclosed in a tense tunica albuginea. The cut surface bulged out and whitish in colour. Representative tissue samples of the mass were fixed in 10% neutral buffered formalin and subjected to histopathological examination. Histopathological examination revealed presence of distended tubules with solid, elongated and palisading tumor cells having pale eosinophilic cytoplasm, darkly stained basally located, oval to spindle-shaped nuclei separated by thick bands of partially hyalinized stromal fibrous tissue. Abundance of this hylanized storma described firmness of the mass (Fig. 2). Hence above histopatholgical findings of the abnormal mass confirmed it to be a Sertoli cell tumor it is in accordance to McEntee (1963), Vegad and Swamy (2010) and Fan and de Lorimier (2013).

Fig. 2. Histopathological photomicrograph revealed presence of distended tubules with solid, elongated and palisading tumor cells having pale eosinophilic cytoplasm, darkly stained basally located, oval to spindle-shaped nuclei separated by thick bands of partially hyalinized fibrous stroma. (H & E, X40)

Small purebred dogs, like black Miniature Dachshund, have a 2.7 times greater risk of cryptorchidism than that of other breeds. Testicular tumors were most often diagnosed in geriatric male dogs ranging from 6 to 13 years of age. Cryptorchid dogs have a risk of testicular tumours 13.6 times that of normal dogs

because of the exposure to atypical environment which resulted in degeneration of the germinal epithelium and loss of exocrine function. Aforementioned statistics were in agreement to our present findings of breed and age predisposition. Owing to the higher risk of neoplasia in cryptorchid testes and atropy of the unaffected testis, justifies the prophylactic ablation of the undescended testis in this case; as also mentioned by Grieco *et al.* (2008), Liao *et al.* (2009), Navya *et al.* (2013) and MacPhail (2013).

Dogs with cryptorchid testes are at 23 times greater risk of developing SCT. SCTs are usually solitary but may be multiple and bilateral with expansile growth, compressing and destroying surrounding testicular tissue. SCTs produce excess estrogenic hormones causing hyperestrogenism, a paraneoplastic manifestation of primary testicular tumors, which has propensity to induce a feminization syndrome. This describes presence of thin skin, hyperpigmentation, alopecia, rough and brittle hair coat in the animal as also recorded by Grieco *et al.* (2008), Liao *et al.* (2009) and Fan and de Lorimier (2013).

References

Boothe, H.W. (2003). Testes and Epididymides. In: Slatter, D.H. (eds.) Textbook of small animal surgery, 3rd edn., Elsevier Science, U.S.A. Pp. 1521-1530.

Fan, T.M. and de Lorimier, L.P. (2013). Tumors of the Male Reproductive System In: Withrow, S.J., Vail, D.M., and Page, R. (eds.) Withrow and MacEwen's small animal clinical oncology. 5th edn., Elsevier Health Sciences., St. Louis, Missouri, U.S.A. Pp. 637-648.

Grieco, V., Riccardi, E., Greppi, G.F., Teruzzi, F., Iermano, V. and Finazzi, M. (2008). Canine testicular tumours: a study on 232 dogs. *J.Comp.Pathol.*; **138**: 86-89.

Liao, A.T., Chu, P.Y., Yeh, L.S., Lin, C.T., and Liu, C.H. (2009). A 12-year retrospective study of canine testicular tumors. *J. Vet. Med. Sci.*; **71**(7): 919-923.

MacPhail, C.M. (2013). Surgery of the Reproductive and Genital Systems. In: Fossum T.W. (eds.) Small Animal Surgery, 4th edn., Elsevier, St. Louis, Missouri, U.S.A. Pp. 840-843.

McEntee, K. (1963). The male genital system. In: Jubb, K.V.F. and Kennedy, P.C. (eds.) Pathology of domestic animals, Volume I, 1st edn., Academic Press, New York. Pp. 367-368.

Navya, M., Sudha, G., Krishna, A. and Krishnaswamy, A. (2013). Sertoli cell tumor in an intact male swiss mountain terrier dog - a case report. *Indian J. Can. Pract.*; **5**(1): 26-27.

Vegad, J.L. and Swamy, M. (2010). Male reproductive system. In: A textbook of Veterinary Systemic Pathology, 2nd edn., IBDC Publishers, Lucknow, India. Pp. 390-392.