SURGICAL MANAGEMENT OF LARGE CUTANEOUS FIBROMA IN A DOG – A CASE REPORT

A.K. Sharma[1], K.K. Singh[2], Kumari Chandrakala[3], Laxmi Kumari[3] and Pankaj Kumar[3]
[1]Assistant Professor, [3]M.V.Sc.Scholar, Deptt. of Veterinary Surgery & Radiology, [2]Professor, Deptt. of pathology
Ranchi Veterinary College, Kanke, Ranchi-834006.
[Received: 23.8.2015; Accepted: 03.3.2016]

A 10 years old male Doberman dog was presented to clinic with the history of huge mass hanging at lateral aspect of hip area. The mass was growing since last 6 months. On examination, it was hard in consistency. Rectal temperature, heart rate and respiration rate was recorded within normal range.The case was diagnosed as fibroma on the basis of histopatholgy. The case operated and it showed uneventful recovery without any complication.
Key words: Dog, Fibroma, Surgical management

A large variety of tumors arise in the skin, which is also a common site for the development of secondary metastatic tumors. Cutaneous tumors represent approximately 1/3rd of the all canine tumors and are of considerable importance in small animal practice (Dobson and Gorman, 1988; Srivastava *et al.,* 2012). Benign lipomas and fibromas are also common superficial tumors in dogs (Priester and McKay,1980). The present paper deals with the surgical management of a large cutaneous fibroma in a dog.

History and Observation

A 10 years old male Doberman dog was presented to the clinic with the history of huge mass hanging at lateral aspect of hip area (Fig.1). The mass was growing since last 6 months. On examination, it was hard in consistency. Rectal temperature, heart rate and respiration rate was recorded within normal range. Haemato- biochemical changes (Hb, TLC and DLC and ALT and AST) was found to be within normal physiological limits. The x- ray examination of thoracic cavity did not reveal any abnormality. Because it was huge in size causing difficulty during locomotion to the animal, it was decidedfor excision.

Fig. 1: Dog with tumor mass on hip area

Fig.2: Excised tumor mass

Treatment and Discussion

The patient was stabilized with administration of Dextrose saline, 300 ml I/V and ceftriaxone @ 500 mg I/M, preoperatively. The surgery was performed under general anaesthesia achieved by administration of Atropine S/C @ 0.04 mg/kg b wt. Xylazine Hcl @ 1mg/kg b wt. Ketamine Hcl @ 5 mg/kgbwt followed by administration of Diazepam @ 1mg/kgbwt intravenously. Maintenance of anaesthesia was done by Ketamine HCL intravenously. Complete surgical excision of the tumour was performed by careful blunt dissection of adjoining muscle and haemostasis (Fig.2). Muscles were apposed with simple

Fig. 3: Animal 8th day post – operatively after surgery

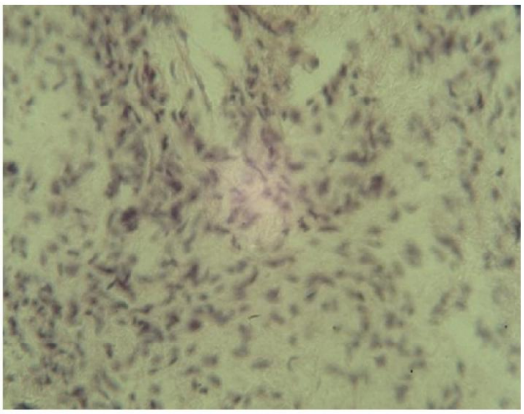

Fig. 4: Photograph showing interlacing bundle of fibrous connective tissue and fibrocytes with fusiformis cells and elongated nuclei (HEx40)

continuous and interlocking suturing pattern using chromic catgut no. 1/0. Dead space was obliterated by subcuticular suture with chromic catgut no.2/0. Skin was closed with cross mattress suture pattern using nylon (Fig.3). Histopathological examination revealed interlacing bundles of fibrous connnetive tissue arranged in a criss – cross pattern at focal places. The fibrocytes were characterized by the presence of fusiform cells with elongated nuclei. No atypical change was observed in the cell population. Histological picture of tissue was suggested as fibroma (Fig.4). Post- operatively animal was administered with Inj. Ceftriaxone @ 20 mg/kg I/M BID for 7 days, Inj. Meloxicam @ 1 mg/ 4 kg b wt. I/M daily for 3 days. The skin sutures were removed on 10th day post-operatively after daily antiseptic dressing.The recovery was uneventful after surgery without complication. The benign tumors are treated by complete surgical excision as also reported by Gross *et al.*(1992) and Aruljothi *et al.,*(2004).

References

Aruljothi, N., Alphonse, R.M.B., Kumar, R. and Varshney, K.C. (2004). Multiple cutaneous myxoma in a dog. *Indian J. Vet. Surg.;* **25**: 52-54.

Dobson, J.M. and Gorman, N.T. (1988). A clinical approach to the management of skin tumors in the dog andcat. *In Practice*; **10**: 55-68.

Gross, T.L., Thrke, P.J. and Walder, G.J. (1992). Neoplastic diseases of the skin. In: Gross, T.L., Thrke, P.J. and Walder, E.J.(Eds). Veterinary Dermatology-A macroscopic and microscopic evaluation of canine and feline skin diseases. St Louis, Mosby, London, Pp. 415-17.

Priester, W. A. and McKay, F.W. (1980). The occurrence of tumors in domestic animals. National Cancer Institute monograph No. 54. Bethseda, Maryland: National Institute of Health. Pp. 166.

Srivastava, A.K., Singh, Bharat, Srivastava, A.K., Sharama, A.K. and Sinha, Neeraj, (2012). Canine Skin and Other Tumours: A Study on Occurrence and Distribution Pattern. *Indian J. Canine Practice;* **4**(2): 168-171.