A CASE REPORT ON TRICHOBLASTOMA IN A LABRADOR DOG

G.K. Sawale[1], D.S. Gavhane, R.R. Rohi, S. Roshini and S.D. Moregaonkar
[1]Asstt. Professor, Department of Veterinary Pathology, Bombay Veterinary College, MAFSU, Western Express Highway,Near Mahananda Dairy, Goregaon, Mumbai-400 065 (India).
[Received: 24.9.2015; Accepted: 15.6.2016]

An oval shaped growth measuring 3cm in diameter, below the jaw was surgically removed from a ten year old female Labrador dog. The growth was firm in consistency and grey-white in colour. Microscopic examination showed basaloid cells arranged in ribbon like cords with palisade appearance and had prominent nuclei with scanty cytoplasm. At few locations, the cells were arranged like cords radiated from central Island of densely packed cells. The features observed were diagnostic of trichoblastoma of mixed (ribbon with medusoid) subtype.
Key words: Hair follicular tumour, Histopathology, Trichoblastoma, Labrador dog.

Trichoblastoma, a benign tumour that arose from primitive hair germ epithelium account for approximately 25.6 per cent (Abramo *et al.*, 1999) of the follicular tumours in the dog. Georgeta *et al.* (2011) reported 28.5 per cent of trichoblastoma among of all benign cutaneous tumors in dog. Trichoblastoma was previously grouped as basal cell tumours in dogs and histologically classified into ribbon, medusoid, trabecular, granular and spindle cell type (Goldschmidt and Hendrick, 2002). The present paper places on record a case of mixed subtype (ribbon with medusoid) trichoblastoma in a ten year old female Labrador dog.

Materials and Methods

An oval shaped growth below jaw was surgically removed by local Veterinarian from a ten year old female Labrador dog and presented to Department of Pathology, Bombay Veterinary College, Mumbai along with the clinical history of the dog. The tissues were preserved in 10% buffered formal saline. The pieces of the growth were processed by routine histopathological techniques to obtain paraffin sections of 5 µm thicknesses and stained with haematoxylin and eosin (Culling, 1963).

Result and Discussions

Grossly, the growth measured 3 cm in diameter at subcutaneous tissue below jaw (Fig. 1-a). The skin over tumour mass appeared irregular and rough. On section, the tumour mass was firm in consistency and grey-white in colour (Fig. 1-b). The gross lesions reported in the present investigation were in accordance with the previous reports (Goldschmidt *et al.*, 2000; Goldschmidt and Hendrick, 2002; Villalobos, 2014).

Fig. 1-a: An oval shaped growth removed from skin below jaw; b- On section, tumour mass appeared gray- white in colour

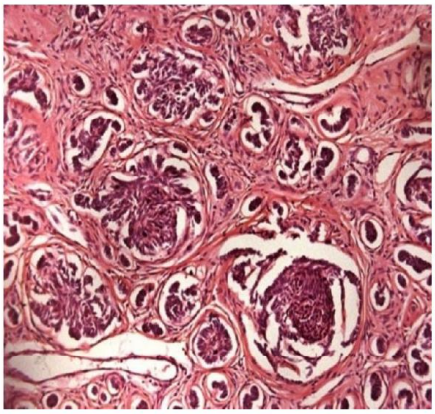

Fig. 2: Neoplastic cells showing medusoid & palisade appearance (HE x 200X)

Goldschmidt and Hendrick (2002) were of the opinion that the trichoblastoma in dogs were generally seen in 4 to 9 year age where as Villalobos (2014) reported that the trichoblastoma generally develop in middle and older age dog. In the present investigation, trichoblastoma was recorded in ten year old dog. The breed such as Kerry Blue Terriers, Bichon Frise and Welsh springer spaniel were reported to be more susceptible to trichoblastoma as also reported by Goldschmidt *et al.* (2000). Villalobos (2014) reported Wirehaired Pointing Griffons, Kerry Blue Terriers and Wheaten Terriers as a most susceptible breed to trichoblastoma. However, present investigation recorded trichoblastoma in Labrador breed which is reported to be at low risk for this tumour as also mentioned by Goldschmidt *et al.* (2000).

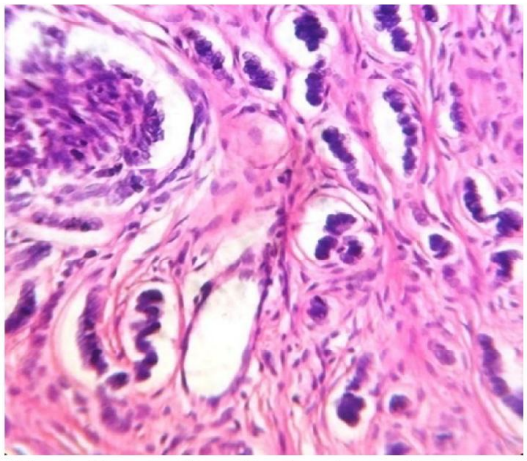

Fig. 3: Neoplastic cells showing palisade appearance (HE x 400X)

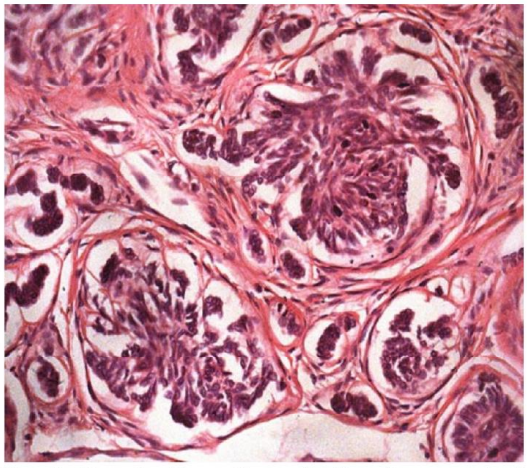

Fig. 4: Neoplastic cells radiating from central aggregate (Medusoid appearance) (HE x 400X)

Abramo *et al.* (1999) and Goldschmidt *et al.* (2000) reported head as a most common site for occurrence of trichoblastoma which support our finding. Campos *et al.* (2014) recorded multiple tricoblastoma in two year old intact male, mixed breed dog.

In this case, histologically, section showed features of trichoblastoma consisting of mixed areas of different subtype *i.e* ribbon with medusoid (Fig. 2). The neoplastic cells predominantly consisted of basaloid cells and had prominent nuclei and scanty cytoplasm. These basaloid cells formed the long cords of branching cells joined together with nuclei and arranged in a palisaded appearance as that of ribbon subtype (Fig. 3). The cords were two or three cell thick and had abundant stroma. At few locations, these cells were arranged like cords of cells radiated from central island of densely packed cells (Medusa head appearance), which had more amount of eosinophilic cytoplasm (Fig. 4). The nuclei were hyperchromatic with inconspicuous nucleoli in both the subtypes. The mitotic figures were low in the cells of ribbon type and were comparatively more in the cells of medusoid type. Basal cells become the germinative cells of the hair follicle and mesenchymal cells become follicular papilla as also reported by Jasik *et al.* (2009). Hence, trichoblastoma is a benign tumor that is derived from the differentiation of a developing follicle to a hair germ as also recorded by Goldschmidt and Hendrick (2002). Wong *et al.* (1993) described features of both trichoblastic fibroma and trichogenic trichoblastoma in a one tumour at a time and suggested that the presence of overlapping histological features can be problematic for practising histopathologists, who rarely encounter these conditions. Similarly, Jasik *et al.* (2009) recorded two cases of mixed subtype of trichoblastoma depicting ribbon with medusoid subtype, out of 39 adnexal tumours studied. They also reported two mixed areas of trichoblastoma consisting granular with medusoid subtype in the same

tumour section. Moreover, Goldschmidt and Hendrick (2002) were of the opinion that the medusoid and ribbon type trichoblastoma were most frequently observed in dogs. The histological lesions described in the present study are in accordance with observations of Campos *et al.* (2014); Goldschmidt and Hendrick (2002) and Jasik *et al.* (2009). Georgeta *et al.* (2011) noted histologically, trichoblastoma as a most frequently diagnosed lesion from 228 dogs showing benign epithelium tumours over a period of four year study with its incidence ranging from 26 to 31%.

The tumour was surgically removed and surgical excision of tumour is the treatment of choice in trichoblastoma. Metastasis in this tumour has not been generally observed. The occurrence of mixed subtype of trichoblastoma consisting ribbon with medusoid in Labrador breed is being a rare case, hence reported.

Acknowledgement

Authors are thankful to the Associate Dean, Bombay Veterinary College, Mumbai for providing research facility for the study.

References

Abramo, F., Pratesi, F., Cantile, C., Sozzi, S. and Poli, A. (1999). Survey of canine and feline follicular tumours and tumour-like lesions in central Italy. *J. Small Anim. Pract.*; **40**(10): 479-481.

Campos, A.G., Cogliati, B., Guerra, J.M. and Matera, J.M. (2014). Multiple trichoblastomas in a dog. *Vet. Dermatol.*; **25**: 48-51.

Culling, C.F.A. (1963). *Hand book of histopathological and histochemical techniques.* 3rd Edn. Butter Worths and Co. (Publishers), Ltd. Landon. Pp. 265-275.

Georgeta, D., Iancu, F., Condrut, E., Curtseit, S., Ciobotaru, E.and Militaru, M. (2011). Overview of the cutaneous benign epithelial Tumors in dog – epidemiological and Morphological aspects. *University of Agronomical Sciences and Veterinary Medicine-Bucharest, Scientific works, C Series,* **LVII (1)**: 225-233.

Goldschmidt,, M.H. and Hendrick, M.J. (2002). Tumors of the skin and soft tissue. *In*: Tumors in domestic animals. Meuten, D. J. (Ed.), Iowa State Press, USA. Pp. 58.

Goldschmidt, M.H., Mcmanus, P. and Goldschmidt, K. (2000). University of Pennsylvania (http://cal.vet.upenn.edu/ projects/derm/Home/ADNEXAL/follic/ blastc.htm,downloadedon21/07/ 2014).

Jasik, A., Kozaczyński, W. and Reichert, M. (2009). Canine skin tumours with adnexal differentiation: Histopathology and immunohistochemistry. *Bull Vet Inst Pulawy*; **53**: 277-283.

Villalobos, A.E. (2014). Overview of Tumors of the Skin and Soft Tissues. Merck Veterinary Manual;Merck Sharp & Dohme Corp., a subsidiary of Merck & Co., Inc., Kenilworth, N.J., U.S.A. http: //www. merckvetmanual.com/mvm/ integumentary_system/tumors_of_the_ skin_and_soft_tissues/overview_of_ tumors _of_the_skin_and_soft_tissues. html.

Wong, T.Y., Reed, J.A., Suster, S., Flynn, S.D. and Mihm, M.C.Jr. (1993). *Histopathology*; **22**(6): 575.