CONCURRENT MICROFILARIASIS AND CHRONIC DERMATOPHILOSIS IN A DOG – A CASE REPORT

A. Arthi[1] and P.V. Tresamol[2]
M.V.Sc Student, Professor and Head, Department of Veterinary Epidemiology and Preventive Medicine, College of Veterinary and Animal Sciences, Mannuthy, Thrissur-680651(Kerala).
[Received: 02.11.2016; Accepted: 29.5.2017]

A five year old female Labrador, presented with inappetance and vomiting with microfilariasis and dermatophilosis was treated with tablet levamisole hydrochloride and tablet clindamycin respectively. Molecular confirmation by polymerase chain reaction (PCR) was done to amplify a 500 bp region of 16S rRNA gene of *Dermatophilus congolensis.* The present case deals with the molecular confirmation and successful therapeutic management of canine dermatophilosis associated with microfilariasis.
Keywords: Clindamycin; Dermatophilosis; Microfilariasis; PCR.

Dermatophilosis is generally a disease of farm animals and relatively rare in companion animals. It causes an acute, subacute or chronic infection characterized by exudative dermatitis and by the formation of hard scabs. Moisture, rainfall, insect bites and wounds are some of predisposing factors (Zaria, 1993). The main predisposing factor in this case was rainfall and persistent exposure to wet marshy areas. This results in the maceration of epidermis thereby releasing zoospores that penetrate deeper layers of skin. The causative agent *D. congolensis* was first isolated from African cattle in Belgian Congo in 1915 by Van Saceghem (Ikpeze, 2004) and he considered this to be a filamentious bacterium.

Case history and observation

A five year old female Labrador was presented to the Teaching Veterinary Clinical Complex, Mannuthy, Thrissur with a history of vomiting and reduced feed intake. On general examination, the animal had an elevated body temperature, pale mucous membranes and enlarged lymph nodes. Abdominal palpation revealed splenomegaly and pain at the epigastric region. The animal had patchy alopecia, circumscribed erythematous lesions on the ventral abdomen and desquamation of epidermis at the interdigital spaces (Fig. 1) in all the limbs with evinced pain on touching. The skin lesions were an incidental finding and were confined to the lower abdomen and interdigital spaces.

Fig. 1 – Interdigital lesions



Fig. 2 - Parallel rows of branching filaments of *D. congolensis*

Materials and Methods

Wet film examination revealed the presence of microfilaria which was found to be sheathed on Giemsa's staining of thick blood smears. No other blood parasites could be detected. Hematology showed anemia (hemoglobin: 7.0 g/dl) and leukocytosis (20.6 x 10^3 /µl). Direct microscopic examination of Giemsa stained smears from the inter digital region revealed coccal zoospores. Sterile swabs were used to collect samples aseptically and primary isolation was done in brain heart infusion agar. The colonies were pinpoint greyish white after incubation for 48 hours at 37^0C. Gram's staining revealed the presence of parallel rows of branching filaments (Fig. 2). The isolate showed sensitivity to clindamycin but was resistant to enrofloxacin, amoxicillin clavulanate, amoxicillin sulbactam and cephalexin.

Treatment was initiated with fluid therapy with dextrose saline at a dose rate of 10 ml / kg body weight and symptomatic therapy was given for the primary complaint. Based on the results of culture and sensitivity the dog was treated with Tab. Bioclan 300mg (Clindamycin) at a dose rate of 20mg / kg body weight s.i.d, *per os* for two weeks. Topically ointment Betadine (povidone iodine) was applied with oral multivitamin supplements and a hematinic.

Extraction of DNA was done using the High Pure PCR Template preparation Kit (Qiagen, Germany), according to the manufacturer's instructions. PCR was performed targeting a 500 bp fragment of the 16S rRNA gene of *Dermatophilus congolensis.* The primer pair, forward primer 5'-ACATGCAAGTCGAACGATGA-3' and reverse primer 5'-ACGCTCGCACCCTACGTATT-3' was used to amplify the region of interest with minor modifications. This was done in a total reaction mixture of 25 µl, consisting of buffer 2.5µl, $MgCl_2$3µl, primer 1 µl each, dNTPs0.75µl, Taq 0.5 µl, sample DNA 5 µl and nuclease free water 11.25µl. The DNA was initially denatured at 95ºC for 1 min, followed by denaturation at 94ºC for 30 s, annealing at 60ºC for 30 s and extension at 72ºC for 1 min. This was done for 32 cycles, and a final extension at 72ºC for 7 min. Five µl of the PCR products was electrophoresed in 1.5% agarose gel containing 3 µl of 10 mg/ml ethidium bromide at 70V for 60 min. A one hundred base pair (bp) marker was used as a molecular size ladder. DNA amplifications were examined and documented in gel documentation (Fig. 3).

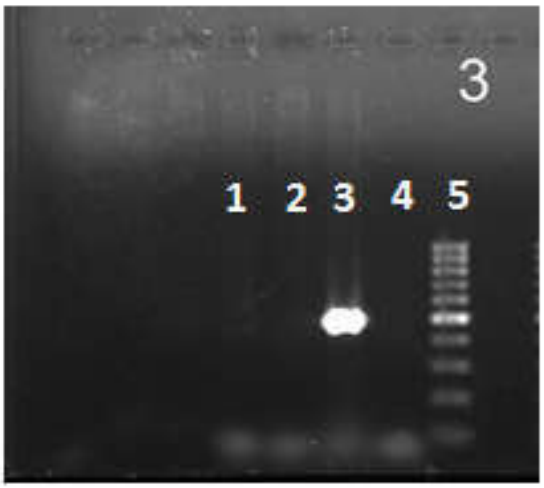

Fig. 3 – Lane 1, 2 and 4 – negative samples,Lane 3 – positive sample of *D. congolensis* with product size 500 base pairs andLane 5 – 100 bp ladder

Results and discussion

The presence of branched, septate filaments with parallel rows of coccoid bodies is the characteristic microscopic feature of *D. congolensis*. Broken skin is generally the route of entry of motile zoospores.

Microfilaria associated dermatitis with plaque formation in the skin of head and limb is common as also reported by Hargis *et al.* (1999). Occasionally animal handlers have acquired infection after a minor skin trauma. Timely diagnosis and treatment is essential as generalized infection can result in dehydration and finally death as also recorded by Ikpeze (2004).

Improvement was noticed in one week post treatment with absence of pain at the paw pads. Tab. Pantoprazole at a dose of 1 mg/kg body weight body and Tab. Levamisole hydrochloride at a dose rate of 10 mg/kg body weight s.i.d, *per os* for seven days was advised for the treatment of microfilariasis. There was complete recovery post treatment.

Reference

Hargis, A.M., Lewis, T.P., Duclos, D.D., Loeffler, D.G. and Rausch, R.L. (1999). Dermatitis associated with microfilariae (Filarioidea) in 10 dogs. *Vet. Dermatol.*, **10:** 95-107.

Ikpeze, O.O. (2004). Dermatophilus infection in Nigeria: A minireview. *Bio Research*, **2:** 37-45.

Jubb, K.V.F. and Kennedy, P.C. (1963). Pathology of Domestic Animals.Vol. 2. 2nd Edn. Academic Press. New York. U.S.A. Pp.606.

Zaria, L.T. (1993). *Dermatophilus congolensis* infection (dermatophilosis) in animals and man. An update. *Comp. Immune. Microbiol. Infect. Dis.*, **16:** 179-222.

LIFE MEMBERSHIP

Membership of the Society is open to Veterinary / Medical Graduates who are actively engaged in the field of Canine Practice. For the membership, please write to **Prof. (Dr.) A.K. Srivastava,** Secretary General or **Dr. Shrish Chandra,** Treasurer, Indian Society for Advancement of Canine Practice, 21/5, Sector-21, Indira Nagar, Lucknow – 226 016 (U.P.) India.

You may download the Form from our website: www.isacp.in

The Life Membership Fee is Rs.1000.00 / $ 25/ £ 18.