UNILATERAL DIFFUSE SEMINOMA IN A DOG

G.S. Shravya[1], C. Jayakumar[2], R.H. Naveen Kumar, P. Rakshitha, J. Smitty and K.B. Dhanush

[1]M.V.Sc. Student, [2]Assistant Professor, Department of Animal Reproduction, Gynaecology and Obstetrics; College of Veterinary and Animal Sciences, Mannuthy, Thrissur (Kerala).

[Received: 07.8.2017; Accepted: 20.3.2018]

{DOI 10.29005/IJCP.2018. 10.1.051-053}

A seven year old non descriptive male dog was presented with a history of unilateral swelling in the scrotal region since four months. Detailed examination of the scrotal sac revealed hard and swollen left testis and a normal right testis. Ultrasonographic examination revealed intact, hyperechoic testicular capsule and non-homogeneous parenchyma. The condition was tentatively diagnosed as interstitial cell tumour or seminoma. The dog was subjected to bilateral orchiectomy and histopathological examination of the affected testicular tissue confirmed the condition as diffuse seminoma.

Keywords: Dog, Seminoma

Testicular tumours are commonly found in dogs above five years of age with a mean age of 10 years (Gokulakrishnan *et al.,* 2014). It accounts for over 10 percent of tumors in male dogs with a considerably increased incidence in animals with cryptorchid testis (Noakes *et al.,* 2009). Three types of testicular tumours depending on the cell type from which they arise are Sertoli cell tumor, Seminoma and interstitial cell tumour. Interstitial cell tumors are the most frequent; followed by seminoma, the next most common canine testicular tumors. Seminomas originate from germinal epithelium of seminiferous tubules and contribute to 35 percent of canine testicular tumors (Roberts, 1971).They are unilateral or bilateral and distinguished by testicular enlargement in intact males to form an intra testicular mass. Cryptorchidism particularly inguinal retained testis and increased ages are identified risk factors (Meuten, 2002).

Case history and Observations

A seven year old non descriptive male dog of 23kg body weight was presented to the University Veterinary Hospital, Kokkalai, Thrissur, Kerala with a complaint of swelling on the scrotal region since four months. Animal was active with a normal appetite and behaviour. Clinical examination revealed distension of scrotal sac and on palpation, the left testis was grossly enlarged, irregular with altered consistency while the right testis was of normal consistency and size. No pain was elicited on palpation of both the testicles and there was no indication of hair fall or feminization. Ultrasonography of the left testis evinced a hyperechoic testicular capsule and a non homogeneous echogenicity of testicular parenchyma (Fig.1). The results of complete blood count and serum biochemistry were normal. A presumptive diagnosis of the condition was made as seminoma or interstitial cell tumour based on history, clinical and sonographic findings and a surgical management with bilateral orchiectomy was decided.

Treatment and Discussion

Following premedication of the dog with Atropine sulphate @ 0.04mg/kg b.wt., I/M, anaesthesia was induced with Xylazine @ 1.1mg/kg b.wt., I/M, Ketamine @ 5mg/kg b.wt., I/M, Midazolam @0.2mg/kg b.wt., I/V and maintained with Xylazine - Ketamine combination. Under standard surgical procedures, an incision was made parallel to the median raphe on the scrotum after the enlarged testis was firmly held against the scrotal skin. Cutting through the skin, dartos and tunica vaginalis, the vascular part of the spermatic cord was ligated and the spermatic cord was severed and the testis was removed.The normal sized right testis was then removed by incising the median scrotal septum.

On gross examination, the affected testis was swollen, irregular, soft in consistency and grayish brown coloured with

haemorrhagic area (Fig. 2). The testis was 8 cm in size and weighed 150 g. The cut section of testis was greyish white with brown discoloration and had ill-defined lobules. Post operative antibiotic therapy with ceftriaxone @ 25mg/kg b.wt., I/M, was provided for 5 days and the dog made an uneventful recovery.

Fig-1: Ultrasonography of the left testis evinced a hyperechoic testicular capsule

Fig-2: Swollen Testis with irregular, soft in consistency;grayish brown with haemorrhagic area

The tumour samples were fixed in 10% neutral buffered formalin for routine histopathology. On histopathological examination, the testicular tissue section showed a tumor arranged in solid sheets. Tumour cells showed moderate amount of cytoplasm, large vesicular nuclei and prominent nucleoli. Mitosis was noted in some neoplastic cells and also, necrotic areas and haemorrhage were seen (Fig. 3).

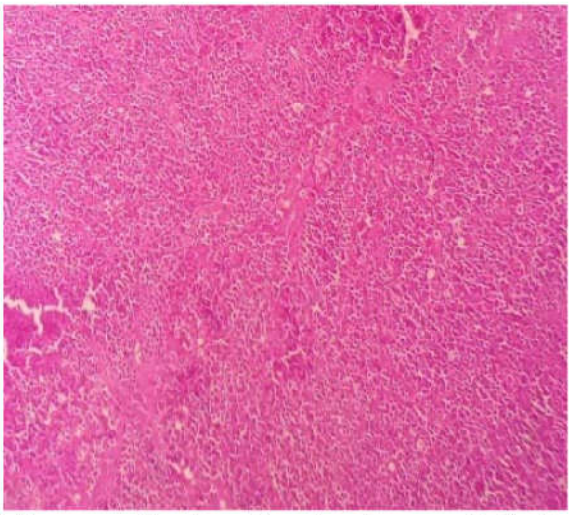

Fig-3: Tumour cells showed moderate amount of cytoplasm, large vesicular nuclei and prominent nucleoli.

A confirmatory diagnosis of the condition was made as seminoma, a germinal cell tumor. Seminoma is often considered a benign tumor of the testis in canines and usually unilateral. Advanced age of the dog would have predisposed to the condition in this case reported because causes may be cryptorchidism or age related as also reported by Daniel *et al*. (2001). No metastasis was evident on thoracic and abdominal radiography in this case as also reported by Withrow *et al.* (2013) that the metastasis of

canine testicular tumors is rare and is less than 10 percent. Seminoma rarely cause any clinical symptoms except the presence of the mass and some dogs exhibiting pain due to pressure from the growing tumour. The tumors in the present study, was diagnosed as a diffuse type seminoma based on histopathological patterns.

Conclusions

Based on the clinical and microscopical findings, it can be concluded that it was a case of unilateral diffuse seminoma.

References

Daniel, J.S.D., Root, K. and Olson, P.N.S. (2001). Disorders of the canine testes and the epididymis. *Am. J. Vet. Res.*, **62**: 1198-1206.

Gokulakrishnan, M., Vijayanand, V. and Thilagar, S. (2014). Clinical Management of Seminoma in 2 Dogs. *Intas Polivet*, **15**: 27-28.

Meuten, D.J. (2002). Tumors in domestic animals. 4th edn., IowaState Press, Iowa, U.S.A. Pp. 561-573.

Noakes, D.E., Parkinson, T.J. and England, G.C.W. (2009). Fertility, subfertility and infertility in male animals.Verterinary Reproduction and Obstetrics. 9th edn., Sounders, Philadelphia, U.S.A. Pp. 745.

Roberts, S. J. (1971). Infertility in male animals.Veterinary obstetrics and genital diseases. 2nd edn., CBS, New Delhi, India. Pp. 677.

Withrow, S.J., Vail, D.M. and Page, R.L. (2013). Tumors of the Male Reproductive System Withrow and MacEwen's Small animal clinical oncology. 5th edn., Sounders, Philadelphia, U.S.A. Pp. 557-571

UNILATERAL UTERINE TORSION IN A DOG AND ITS MANAGEMENT BY OVARIOHYSTERECTOMY

C. Jayakumar[1], J. Smitty[3], S. Raheema[3] and M.O. Kurien[2]
[1]Assistant Professor, [2]Professor & Head, [3]M.V.Sc. Student, Department of Animal Reproduction,Gynaecology and Obstetrics, College of Veterinary and Animal Sciences ,Mannuthy, Thrissur (Kerala).
[Received: 29.8.2017; Accepted: 26.3.2018]
{DOI 10.29005/IJCP.2018. 10.1.054-055}

Uterine torsion is rare and life-threatening condition in a bitch. A four year old, full term pregnant non-descript bitch was presented to University Veterinary Hospital, Kokkalai, KVASU in a shock like state with a blackish vaginal discharge. No fetal parts were palpable on vaginal examination. Palpation revealed a tensed abdomen, trans-abdominal sonography revealed non-viable fetuses with hyper echoic uterine contents. Serosanguinous peritoneal fluid, purplish discoloration of uterus and torsion of the gravid right uterine horn at its base was noticed on laparotomy. An ovariohysterectomy was performed and the bitch made an uneventful recovery.
Keywords: Bitch, Ovariohysterectomy, Torsion, Uterus.

Uterine torsion, rotation of the uterus on its longitudinal axis is first reported by Boutrolle in 1766 (Fleming, 1930). It's an unusual and life threatening situation in the bitch. Unilateral torsions are more common than bilateral in canines and the disorder is more common in the pregnant than non pregnant uterus (Shull *et al.*, 1978). Torsion is usually limited to a uterine horn or part of the horn in bitch and queen whereas, in other species, torsion is of the uterine body (Barrand, 2009). The associated problems with canine uterine torsion include dystocia, peritonitis, endotoxic shock and death (Misumi *et al.*, 2000). This report describes unilateral uterine torsion in a non-descript bitch and its successful management by ovariohysterectomy.

Case History and Observations

A four year old, pleuriparous, non-descript bitch, bred 64 days before was presented to small animal obstetrical ward of University Veterinary Hospital, Kokkalai, KVASU with the history of inappetence and recumbence since two days, with futile straining efforts the previous day. The recumbent bitch was dull and the temperature was 97.7^{0}F. Respiration and pulse rate was also in the lower range????. Vaginal examination revealed slight blackish discharge, but had no reflex straining to feathering of the vagina. Abdominal palpation revealed tense and distended uterine horns, but appreciation of the fetal skeleton was not obvious. Trans-abdominal sonography revealed non-viable fetuses with hyper-echoic uterine contents. Though the clinical signs, vaginal examination and sonographic findings were suggestive of obstructive dystocia, the precise cause of obstruction was not determined. Taking into consideration the bad health condition of the dog, delayed nature of the problem, lack of feathering response and blackish vaginal discharge, it was decided to perform an emergency cesarean section.

Treatment and Discussion

Under anesthetic induction with propofol @ 5 mg/kg and 2% isoflurane maintenance, laparotomy was performed through a right flank incision. Following laparotomy, more of serosanguinous peritoneal fluid and purplish discoloration of uterus was observed. Careful examination revealed torsion of the gravid right uterine horn at its base (Fig. 1). Being a delayed case with emphysematous fetuses along with cyanosis and necrosis of the twisted uterus, an ovario-hysterectomy was performed. Thorough cleansing of the peritoneal cavity was carried out with normal saline and further, the laparotomy wound closed under standard surgical procedures. The removed uterus revealed five dead, decomposed fetuses and haematometra (Fig. 2). Post surgical antibiotic treatment with Ceftriazone- tazobactum @ 15 mg/ kg b.wt, Metronidazole @ 20 mg/kg b.wt and supportive treatments with Ringers lactate @