USG GUIDED BIOPSIES OF VISCERAL ORGANS IN DOGS

Ankur Debnath[1] and Debaki Ghosh[2]

[1]M.V.Sc. Student, [2]Professor, Department of Surgery & Radiology; Faculty of Veterinary & animal Sciences; West Bengal University of Animal and Fishery Sciences, Kolkata, (West Bengal), India.

[Received: 24.7.2017; Accepted: 27.3.2018]

{DOI 10.29005/IJCP.2018. 10.1.056-059}

The ultrasound guided core needle biopsy (USG-CNB) and ultrasound guided fine needle aspiration biopsy (USG-FNAB) for various abdominal organs on 10 clinical cases of dogs were carried out. The accuracy of the biopsy collection technique was appreciably high for collection of biopsy from liver, spleen and prostate, but unsatisfactory for kidney tissue. Ultrasonography helped in characterization of echo texture thereby organal parenchymal change as well as determination of size. It was concluded that USG-CNB with (core needle biopsy instruments) using free hand technique was an easy, safe and accurate technique for obtaining sufficient and desired tissue for histopathological diagnosis in cases of hepatic, spleenic and prostate affections in dogs.

Keywords: Fine needle aspiration biopsy, Kidney, Liver, Prostate, Ultrasound guided core needle biopsy (USG-CNB), Ultrasound guided fine needle aspiration biopsy (USG-FNAB).

The affection of visceral organ in dogs is common. The diagnosis of *these* visceral organ affections is mainly based on the histor y, clinical signs, physical examination, blood biochemistry and imaging studies. The clinic al, radiological and hemato-biochemical tests are usually inadequate for the establishment of an etiologic diagnosis, specific therapy and prognosis. Ultrasonography has the ability to differentiate various soft tissue densities, whi-ch makes it possible to locate organs and lesio -ns not visible radiographically. For different oncological studies collection of biopsy and thereby evaluation is a gold standard for conf-irmatory diagnosis. But many times the biops -y collected grossly may become false negativ -e. The ultrasound guided biopsy (USGB) can help to assess an organ function without surgi -cal exploration to definitely diagnose the con -dition through histopathological/cytological examination. Several methods for obtaining biopsy samples of abdominal organs in small animals have been described including percut -aneous biopsy (De Rycke *et al.*, 1999), keyh-ole techniques (Haris *et al.*, 2011) and biopsy during laparotomy or laparoscopy (Isaza *et al.*, 2003). Ultrasound guided biopsy has become a well-recognized technique used by sonologist for histopathological characterizat-ion of biopsised tissue. The technique of USG-CNB and USG-FNAB is least expensiv -e, rapid, and minimally invasive, hassle free and more accurate than blind punctures. The art of USG-CNGB and USG-FNAB needs practice and reports are also scanty in animals. Therefore, present study was carried out to assess the efficacy and diagnostic value of ultrasound guided biopsy and ultrasound guided fine needle aspiration biopsy in cases of various organal affections in dogs.

Materials and Methods

The present study was conducted on 10 clinical cases of dogs of either sex, aged 8 months to 12 years weighing 10 to 36 kg presented in Department of Veterinary Surgery and Radiology, West Bengal University of Animal and Fishery Sciences, Kolkata-37, India, with varying symptoms of abdominal complains. All the animals were subjected to systematic evaluation for diagnosis of diseases. Hemato-biochemical parameters including serum Alkaline Phosphatase (AKP), Serum Glutamic Pyruvic Transaminase (SGPT), Serum Glutamic Oxaloacetic Transaminase (SGOT), Blood Urea Nitrogen (BUN), creatinine (SC), Total leucocyte count (TLC), Differential Leucocytecount (DLC), Haemoglobin (Hb), total protein and albumin were estimated depending upon the case. Survey abdominal radiographs were taken. Two–dimensional, B-mode ultrasonographic examination of whole abdomen was carried out. After thorough analysis of the results of all investigations the animals justified for USG

Part of M.V.Sc. Thesis

guided biopsies were prepared in routine way. The ultrasound guided core-needle biopsy (USG-CNB) samples were collected in all 10 cases using a tru-cut core disposable biopsy needle of size 16G X 11.25 cm and 14G x15cm in length from the suspected and target part of the organ. The length of sample notch was 2.0 cm and depth of the penetration was 22 mm. The USG-CNB was carried out in dorsal recumbency in all animals. In few cases local infiltration anesthesia was done where patients were non-cooperative during the procedure. The needle was pierced at an angle from ultrasound transducer through the skin, as the organ was being visualized on the monitor (Fig.1). Biopsy of organ was made in maximum one or two attempts and a post biopsy scan was done to check the haemorrhage. Smears were made from tissue samples and processed for cytological evaluation. The tissue samples obtained were then stored in 10% buffered formalin for histopathological examination.

The ultrasound guided fine needle aspiration biopsy (USG-FNAB) was collecte -d from the samples identified sonographical -ly as anechoic space occupying lesion throu-gh a 2ml hypodermic plastic syringe fitted with 27 G, 1.5 to 2 inch needle under USG imaging guidance. The needle was introduce -d under routine aseptic measure through the USG imaging guidance and once the tip of the needle was observed to reach the target area, the aspirate was collected. In case of failure of collection of aspirate, second attempt was made with separate needle. The smears were prepared from the aspirated sample collected by USG- *FNAB* and fixed, stained for histopathological studies.

Results and Discussion

The selected 10 clinical cases of dogs from th e pool which were presented for various hepat ic, spleenic, renal and prostate affections were included in the present study. All the dogs were subjected to clinico-physical, radiograph ic, ultrasonographic, and hemato-biochemical studies before USG-CNB or USG-FNAB.

Table showing affection of the organs and type of biopsy collection technique

Organ from which Biopsy was collected	No	Technique of biopsy collection	
		USG-CNB	USG-FNAB
Liver	4	3	1
Spleen	2	2	0
Kidney	2	2	0
Prostate	2	1	1

Liver: On the basis of haemato-biochemiacal, clinical and radio-imaging studies one animal was suspected for hepatic cyst and thereby aspirate was collected under USG-FNAB. The clinical signs in that dog included vomiting, abdominal distension, reduced feed intake, and black colored loose faeces with elevated SGPT and AKP. Ultra sonogram at right paracostal area adjacent to xyphoid showed presence of anechoic area surrounded by hyperechoic wall adhered with hepatic lobe. The anechogenecity in USG is suggestive of the evidence of any fluid pocket containing either blood, cystic fluid or any other fluid as happens in liver haematoma, cyst and abscess respectively.

The cytological changes of USG-FNAB in this cases evidenced degenerated and necrosed hepatocytes admixed with inflammatory cells (Fig. 2). Similar cytological findings were also reported by Bhadwal (2007). The increased level of SGOT may also be associated with leakage following altered membrane permeability as also reported by Rivera-Sanfeliz et *al.* (2005). The loose faeces in the liver disease could be due to cholestasis caused by endotoxins and increased resistance to portal blood flow, leading to congestion of intestinal vasculature, decreasing intestinal water resorption. Accurate radiographic evaluation of generalized and mild changes in hepatic size has been found to be difficult.

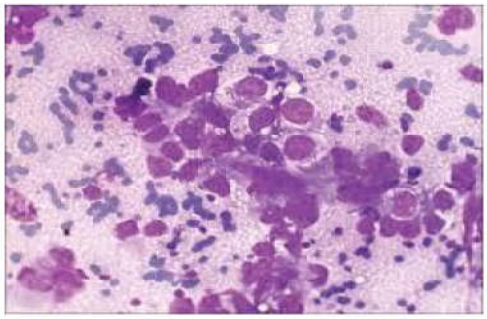

Fig.1. Sonogram showing hypo echoic liver parenchyma along with hyperechoic areas and tip of the needle (N) in the hepatic parenchyma duringUSGCNB. Fig.2. Photomicrograph of hepatic cyst, The aspirate consists of hepatocytes admixed with inflammatory cells (HE X100)

***Spleen*:** The spleen of two dogs appeared to be enlarged in radiograph and the same dogs had ultrasonographycally spleeno-megaly wh ere the edge of the spleen was found extended beyond the costal arch reaching mid ventral aspect of abdomen. The echogenecity decreas -ed than a normal spleen parenchyma and at places there were presence of hyperechoic fo ci spreading the entire spleen with altered arc -hitecture of the organ. The clinical signs of diarrhea, vomiting, lack of appetite, abdomina -l pain, lethargy and reduced activity and elev -ated rectal temperature, heart rate and respira tion rate were evidenced. Total platelet count, SGOT, SGPT and AKP values were elevated. The radiographic and ultrasonographic findin-gs were indicative of alteration in size or struc ture of the spleenic parenchyma. The USGB samples were taken from these animals for further study.

The histological observation revealed that the red pulp tended to be enlarged, while the white pulp tended to be reduced with increase -s in portal pressure and weight of the spleen. It also histologically revealed an increase in the spleenic sinus-like structure, narrowing of the spleenic cords, fibrosis due to reticular cell proliferation singly-scattered and clusters of foamy macrophages in the red pulp and fibrosis around the central artery in the white pulp as also recorded by Jankowski (2003) in a dog suggestive of spleeno-megaly (Fig.3).

Prostate: Two dogs, of more than 10 years age, were observed with constipation, blood stained urethral discharge, blood in the urine. The serum urea nitrogen, creatinine were elevated with eosinoophilia. The radiographs of the abdomen showed enlarged prostate. On ultrasonography the prostatic parenchyma was observed moderately echogenic with a coarse but even texture. The prostate capsule looked to be thickened, hyperechoic and mass tissue pressing the intraprostatic urethra.

The histological findings in such prostate tissue collected under ultrasonography guided biopsy technique showed extensive acinar dilatation lined by prominent hypertrophied epithelial cells as also reported by Hoppe *et al*, (1986). Some residual islands of normal glandular hyperplasia were also seen in the periphery of the gland suggestive of benign prostatic hyperplasia (Fig. 4).

***Kidney*:** Two dogs which had dyusurea, azotaemia, anaemia and ultrasonographically features of atrophied kidneys with loss of cortico-medullarry junction thus suspected for chronic renal failure. The dogs were attempted for USG-CNB of cortex but failed as the target tissues could not be collected as evidenced from the microscopic examination of the collected tissue after processing. In both cases the attempt to collect core biopsy with the help of both Tru-Cut biopsy needle and Bard Max core biopsy gun were unsuccessful. The kidneys are floating organ as a result of which biopsy needle could not strike the organ while attempted under USG guidance due to their mobility.

In the present study, ultrasonographic findings correlated with the hemato-biochem-ical parameters in all the ten dogs and by US-G it was possible to identify alterations in int

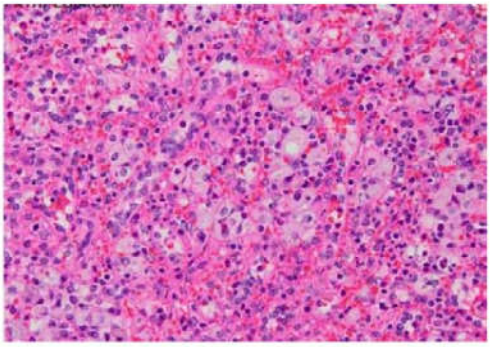

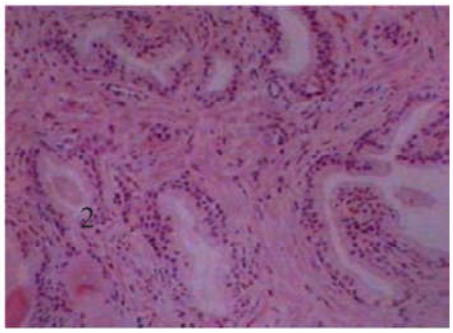

Fig.3. Photomicrograph of spleen showing Spleeno-megaly, Note the presence of singly-scattered and clusters of foamy macrophages in the red pulp. In the absence of hyperplastic follicles patient (HE X100) . Fig.4. Photomicrograph of prostate gland with increased stromal tissue and occasionally cystic change patient. (HE X100).

-ernal hepatic, prostate and spleen architectur-e and parenchyma. The cytological/histologic -al findings gave the confirmatory diagnosis which corroborated with the clinical, hemato-biochemical and ultrasonographic findings. Radiography was not much helpful in the diagnosis of the diseased conditions of liver and spleen in most cases. However, spleenomegaly and hepatomegaly could be diagnosed on the lateral radiographs.

Conclusions

The techniques of USG-CNB and US-GFNAB were practically effective. The accu -racy of the technique was 100% in case of collection of biopsy tissue from liver, spleen and prostate but not satisfactory for kidney. Ultrasonography helped in characterization of organal parenchyma for change in size and echo texture. It was concluded that USG-CN B using free hand technique was an easy, safe and accurate technique for obtaining sufficien t and good quality tissue for histopathological diagnosis in cases of hepatic, spleenic and prostate affections in dogs.

References

Bhadwal, M.S. (1997). Ultrasonographic studies on characteristics of abdominal organs, tendons and joints in health and disease in dogs. Ph.D. Thesis. Punjab Agricultural University, Ludhiana (Punjab), India.

De Rycke, L.M.J.H., Van Bree, H.J.J. and Simoens, .J.M. (1999). Ultrasound-guided tissue-core biopsy of liver, spleen and kidney in normal dogs. *Vet. Radiol. Ultrasound,* **40**: 294-299.

Isaza, R., Ackerman, N. and Schumacher, J. (1993). Ultrasound Guided Percutaneous Liver Biopsy In Snakes. *Veterinary Radiology & Ultrasound*, **34**: 6.

Jankowski, M. (2003). Usefulness of biopsy performed under control of ultrasonograp-hy in diagnosing nephropathy in dogs. *Polskiego Towarzystwa Nauk Weterynaryjnych,* **59**(2): 137-140.

Hares, H., Smets, P., Pey, P., Piron, K., Daminet, S. and Saunders, J.H. (2011). Contrast Harmonic Ultrasound Appearance of Consecutive Percutaneous Renal Biopsies in Dogs.*Veterinary Radiology & Ultrasound*, **52**: 6.

Hoppe, F.H., Hager, D.A., Poulos, P.W., Ekman, S. and Lindgren, P.G. (1986). A Comparison of manual and automatic ultrasound guided biopsy techniques. *Veterinary Radiology,* **27**: 4.

Rivera-Sanfeliz, G., Kinney, T.B., Rose, S.C. Agha, A.K., Valji, K., Miller, F.J. and Roberts, A.C. (2005). Single-pass percutaneous liver biopsy for diffuse liver disease using an automated device: experience in 154 procedures. *Cardiov-asc. Intervent. Radiol.*, **28**(5): 584-588.